Научный обзор | Review
DOI: https://doi.org/10.35693/SIM679557

This work is licensed under CC BY 4.0
© Authors, 2025

Myocardial bridges and proximal atherosclerosis of the coronary arteries: pathogenetic interrelation and clinical significance

Barseg Yu. Kolyan[1], Artur V. Margaryan[2], Sergei N. Chemidronov[3]

[1]Tolyatti City Clinical Hospital No. 2 named after V.V. Banykin (Tolyatti, Russian Federation)
[2]Tyumen State Medical University (Tyumen, Russian Federation)
[3]Samara State Medical University (Samara, Russian Federation)

Abstract

Myocardial bridges (MB) are a congenital anomaly in which the coronary artery is partially immersed in the myocardium. The prevalence of MB varies from 0.5% to 87%, depending on the diagnostic method: selective angiography detects 0.5-18% of cases, whereas CT angiography, up to 73%.

An analysis of 22 peer-reviewed papers (1986-2023) showed that in 98% of the cases MB is associated with proximal atherosclerosis due to hemodynamic disorders (turbulent blood flow, high pressure gradient). However, some studies deny a direct link or point to the potential protective effect of MB. Systolic compression of the artery causes myocardial ischemia, especially in cases of left ventricular hypertrophy or microvascular dysfunction. Clinical manifestations range from asymptomatic to angina pectoris, ACS, and sudden death. Treatment includes beta-blockers, stenting, and myotomy, but the lack of randomized trials limits universal recommendations. The contradictions in the data emphasize the need to integrate morphological and functional imaging, as well as to personalize therapy. Long-term cohort studies, risk stratification algorithms using AI, study of the angular anatomy of coronary arteries may be prospective lines of further research.

Keywords: myocardial bridge, atherosclerosis, coronary arteries, hemodynamics, myocardial ischemia.

Conflict of interest: nothing to disclose.

Citation
Kolyan BYu, Margaryan AV, Chemidronov SN. **Myocardial bridges and proximal atherosclerosis of the coronary arteries: pathogenetic interrelation and clinical significance.** *Science and Innovations in Medicine.* 2025;10(4):XX-XX.
https://doi.org/10.35693/SIM679557

Information about authors
***Barseg Yu. Kolyan** – MD, Head of the X-ray diagnostics of the Radiological Diagnostics Department.
ORCID: https://orcid.org/0009-0000-5065-7922
E-mail: b-eg84@mail.ru
Artur V. Margaryan – MD, Dr. Sci. (Medicine), Professor of the Department of Topographic Anatomy and Operative Surgery.
ORCID: https://orcid.org/0000-0003-3497-8157
E-mail: vanic13@mail.ru
Sergei N. Chemidronov – MD, Dr. Sci. (Medicine), Associate professor, Head of the Department of Human Anatomy.
ORCID: https://orcid.org/0000-0002-9843-1065
E-mail: s.n.chemidronov@samsmu.ru
Corresponding Author

Received: 12.05.2025
Received: 31.08.2025
Published: 25.09.2025

Миокардиальные мостики и проксимальный атеросклероз коронарных артерий: патогенетическая взаимосвязь и клиническая значимость

Б.Ю. Колян[1], А.В. Маргарян[2], С.Н. Чемидронов[3]

[1]ГБУЗ СО «Тольяттинская городская клиническая больница №2 имени В.В. Баныкина» (Тольятти, Российская Федерация)
[2]ФГБУ ВО «Тюменский государственный медицинский университет» Минздрава России (Тюмень, Российская Федерация)
[3]ФГБОУ ВО «Самарский государственный медицинский университет» Минздрава России (Самара, Российская Федерация)

Аннотация

Миокардиальные мостики (ММ) – врожденный вариант анатомии, при которой коронарная артерия частично погружена в миокард. Распространенность ММ варьирует от 0,5% до 87% в зависимости от метода диагностики: селективная ангиография выявляет 0,5–18% случаев, КТ-ангиография – до 73%.

Анализ 22 рецензируемых работ (1986–2023 гг.) показал, что ММ ассоциированы с проксимальным атеросклерозом в 98% случаев из-за гемодинамических нарушений (турбулентный кровоток, высокий градиент давления). Однако часть исследований отрицает прямую связь или указывает на потенциальный защитный эффект ММ. Систолическая компрессия артерии вызывает ишемию миокарда, особенно при гипертрофии левого желудочка или микрососудистой дисфункции. Клинические проявления варьируют от бессимптомного течения до стенокардии, ОКС и внезапной смерти. Лечение включает β-блокаторы, стентирование и миотомию, но отсутствие рандомизированных исследований ограничивает универсальные рекомендации. Противоречия в данных подчеркивают необходимость интеграции морфологической и функциональной визуализации, а также персонализации терапии. Перспективными представляются долгосрочные когортные исследования, разработка алгоритмов стратификации риска с использованием ИИ, а также изучение ангулярной анатомии коронарных артерий.

Ключевые слова: миокардиальный мостик, атеросклероз, коронарные артерии, гемодинамика, ишемия миокарда.

Конфликт интересов: не заявлен.

Для цитирования:
Колян Б.Ю., Маргарян А.В., Чемидронов С.Н. **Миокардиальные мостики и проксимальный атеросклероз коронарных артерий: патогенетическая взаимосвязь и клиническая значимость.** *Наука и инновации в медицине.* 2025;10(4):XX-XX. DOI: https://doi.org/10.35693/SIM679557

Сведения об авторах
***Колян Барсег Юрикович** – заведующий кабинетом рентгенологической диагностики отделения лучевой диагностики.
ORCID: https://orcid.org/0009-0000-5065-7922
E-mail: b-eg84@mail.ru
Маргарян А.В. – д-р мед. наук, профессор кафедры топографической анатомии и оперативной хирургии.
ORCID: https://orcid.org/0000-0003-3497-8157
E-mail: vanic13@mail.ru
Чемидронов С.Н. – д-р мед. наук, доцент, заведующий кафедрой анатомии человека.
ORCID: https://orcid.org/0000-0002-9843-1065
E-mail: s.n.chemidronov@samsmu.ru
Автор для переписки

Список сокращений
ММ – миокардиальный мостик; КТ – компьютерная томография; ПАБ – проксимальная атеросклеротическая бляшка; ИБС – ишемическая болезнь сердца; ИМ – ишемия миокарда; ОКС – острый коронарным синдром; КАГ – селективная коронарная ангиография; КА – коронарная артерия; КТ-КАГ – компьютерная томографическая коронарная ангиография; ПМЖВ – передняя межжелудочковая ветвь.

Получено: 12.05.2025
Одобрено: 31.08.2025
Опубликовано: 25.09.2025

INTRODUCTION

A myocardial bridge (MB) is an anatomical phenomenon in which the coronary artery is partially immersed in the myocardium and exposed to systolic compression. According to autopsy and modern visualization data, the prevalence of MB is 40-86%, however, their clinical significance remains a subject of discussion. Historically, the MB were considered benign, but the newest research data relate them with the ischemia of the myocardium, proximal atherosclerosis and acute coronary events.

In this review, we systematized the data on the correlation of the MB with the development of proximal atherosclerotic plaques (PAP), their role in the pathogenic mechanism of the coronary heart disease (CHD) and the efficiency of therapeutic approaches. We focused on the need of risk stratification and integration of functional methods of assessment of hemodynamics (fractional flow reserve) to optimize case management of patients with MB.

We analyzed over one hundred publications from PubMed and eLibrary databases and selected over twenty peer-reviewed articles published in 1986-2023 for a detailed analysis. The articles selected for analysis meet at least two of the following criteria: focus on the presence or absence of the correlation between MB and PAP; MB incidence rate; presence or absence of the correlation between MB and myocardial ischemia (MI); use of visualization methods (CT-angiography, invasive coronography), as well as autopsy data; clinical, experimental or histological data; additional parameters such as age group; patients with acute coronary syndrome (ACS); number of investigated patients **(Table 1)**. The articles used in this review were additionally structured and analyzed for descriptions of localization and parameters of MB, pathophysiological mechanisms in the tunneled artery, clinical significance and therapeutic methods.

ANALYSIS OF METHODS OF IDENTIFICATION OF MYOCARDIAL BRIDGES

Many researchers conclude that MB is found in every third case. The least sensitive (0.5% [1] to 18% [2]) method of MB diagnostics is selective coronary angiography (CAG) **(Fig. 1)**.

A diagnostic symptom of the MB is the 'milking effect' and/or the 'step up-step down' phenomenon caused by the muscle contraction during systole. It is to be noted that the CAG of the coronary arteries (CA) is the gold standard in diagnosing hemodynamically significant stenosis of the coronary arteries or bypass angiography. It has some technical limitations as compared to other new methods of visualization, e.g. intravascular ultrasound imaging and multi-slice spiral computed coronary angiography (CT-CAG). CT-CAG allows for a better visualization of the MB, from 26.6% [3] to 73% [4] of cases. CT identifies the MB as a fragment of an artery partially or completely immersed in the myocardium. The latest developments in functional assessment further improve the diagnostic value of CT-CAG in the identification of hemodynamically significant MBs **(Fig. 2)**.

It follows from the autopsy data that MBs present greater variability than identified by the above mentioned examination methods. The lowest result (8% [5]) was described in the sample of 975 autopsies (without regard to ACS status). In another study, also without ACS sample, the authors were able to identify presence of MBs in 40% of the cases [6]. The study involving surgical treatment of pediatric patients with MBs aged 11-20 with ACS symptoms reported high incidence of MBs, up to 86% [7]. It is worthwhile mentioning the results of a study of 1986 reporting a similar result of 84% [8]. Review articles and meta-analyses show the average incidence rate of в 19% [9], 24.8% [10], and intervals of 0.5–86% [11] and 5–86% [12]. Such a significant variance of the interval of identified MBs within the same study method may be related to specifics of interpretation and classification. Thus, the relatively superficial MBs (0.5 mm) may have been disregarded by some researchers. Another important factor is that out review considers publications both with a single clinical observation [13] and a largest study involving CAG in 11267 patients [14].

PATHOPHYSIOLOGY OF THE MYICARDIAL BRIDGE

Almost all of researchers concluded that the great majority of the MBs are localized in the anterior interventricular branch of the left descending artery (LAD). The most prevalent localization is the middle third of the branch (68.7%), proximal third (4.5%), distal third (26.8%), and the entire basin of the LAD (92.6%). In such locations as the circumflex of the left coronary artery, the obtuse marginal branch, diagonal branches and the basin of the right coronary artery, the bridges are represented in equally minimal quantities [15]. The depth of the MB location varies within 1.0-2.7 mm, the length within 8.9-15.8 mm; the muscle index of the MB (product of the length and depth of the bridge) was 10.1–42.4. Another study produced the following results: depth of 1-10 mm, length of 10-30 mm [15, 16]. No credible correlation with

Author, year	Methods	N	Age	MBs identified	ACS patients	MB-MI correlation	MB-PAP correlation
Bagmanova ZA. 2007 [1]	Review	-	Adults	0.5–86%	-	Y	Y/N
Jiang L, et al. 2018 [2]	CAG	6774	Adults	18%	Y	N	N
Nakaura T, et al. 2014 [3]	CT-CAG	188	Middle age	26.60%	Y	-	Y
Aparci M, et al. 2016 [4]	CT-CAG	34	Adults	73%	Y	-	Y
Micic-Labudovic J, et al. 2015 [5]	Autopsy	975	Adults	8%	-	Y	-
Lucena JD, et al. 2023 [6]	Autopsy	50	Adults	40%	-	Y	-
Alsoufi B, et al. 2018 [7]	Surgery	14	Children	86%	Y	Y	Y
Ishii T, et al. 1986 [8]	Autopsy	642	-	84%	Y	Y	Y
Hostiuc S, et al. 2018 [9]	Meta-analysis	-	Adults	19%	-	-	Y/N
Hong L, et al. 2014 [10]	Meta-analysis	5486	-	24.80%	Y	N	-
Yuan SM, et al. 2016 [11]	Review	-	-	0.5–86%	-	Y	Y
Starodubov OD, et al. 2023 [12]	Review	-	-	5–86%	-	Y	Y/N
Zhalilov AK, et al. 2023 [13]	Clinical case	1	50 y.o.	Y	Y	Y	-
Jiang X, et al. 2021 [14]	CAG	11267	Adults	9.41%	Y	Y	-
Kabak SL, et al. 2020 [15]	CT-CAG	61	-	36%	Y	-	Y/N
Lee MS, et al. 2015 [16]	Review	-	Adults	5–86%	Y	Y	-
Tian SP, et al. 2014 [17]	CT-CAG	9862	Adults	32.30%	Y	-	Y
Hong H, et al. 2014 [18]	CT-CAG	644	Adults	100%	Y	-	Y
Corban MT, et al. 2014 [19]	Review	-	Adults	40–80%	-	-	Y
Bruce C, et al. 2023 [20]	Meta-analysis	3008	Children and adults	-	Y	Y	-
Mirzoev NT, et al. 2023 [21]	Review	883	Adults	14.40%	Y	Y	Y
Sizov AV, et al. 2023 [22]	Clinical case	1	43	5–87%	Y	Y	Y

Table 1. *Selection and analysis of literature. MB – myocardial bridge; ACS – acute coronary syndrome; MI – myocardial ischemia; PAB – proximal atherosclerotic plaque; CT-CAG – computed tomographic coronary angiography; CAG – selective coronary angiography*

Таблица 1. *Отбор и анализ литературы. ММ – миокардиальный мостик; ОКС – острый коронарный синдром; ИМ – ишемия миокарда; ПАБ – проксимальная атеросклеротическая бляшка; КТ-КАГ – компьютерная томографическая коронарная ангиография; КАГ – селективная коронарная ангиография*

the sex was found: one publication states that women demonstrate higher incidence of MBs than men (10.75% vs. 7.31%) [2], while another states a reverse proportion (4.03% vs. 9.35%) [5].

A direct average correlation was established between the morphometric parameters of the MB: the deeper the position of the fragment of the coronary artery, the greater the length of that section (direct average credible non-linear relation) [16]. Almost in all studies, along with multiple morphometric data on MB parameters (length, depth and their relation, distance to bifurcation, etc.), their localization and incidence rate, the authors were consistent in ignoring the angular structure of the coronary arteries and the nearest branches with respect to the tunneled segment. We believe that this could be quite significant with respect to the major driver of the proximal atherogenesis of the coronary artery, namely, the hemodynamic mechanisms in the vessel.

Compression of the tunneled fragment of the coronary artery during systole is above doubt, whereas the hemodynamic significance of the vessel stenosis is disputable and requires functional diagnostic methods. The degree of stenosis depends on the depth and the length of the MB and lies within 20% to 99%. The effective perfusion of the myocardium depends on the heart rate [13, 15]. The greater portion of the coronary circulation occurs during the diastole, and the average ratio of the systolic and diastolic circulation is 0.22 and 0.85 in the left and right coronary arteries, respectively. It would seem that the systolic compression of the MB is to cause but a mild effect on the total effective perfusion of the

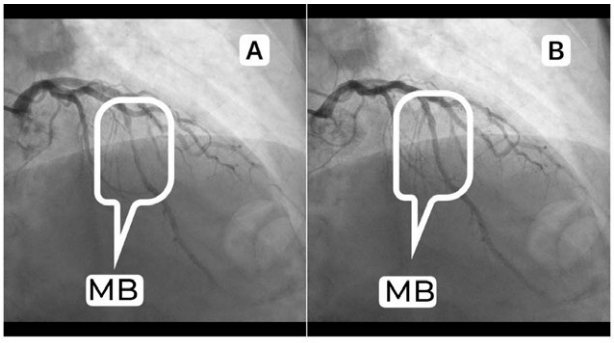

Figure 1. *Typical characteristics of the myocardial bridge under angiography. Image (A) shows a MB fragment undergoing systole compression. In the same artery, the MB segment is not compressed during diastole (B).*

Рисунок 1. *Типичные характеристики ММ при КАГ. На изображении (А) визуализируется фрагмент ММ, подвергающийся компрессии в систолу. В той же артерии во время диастолы (В) сегмент ММ не подвергается компрессии.*

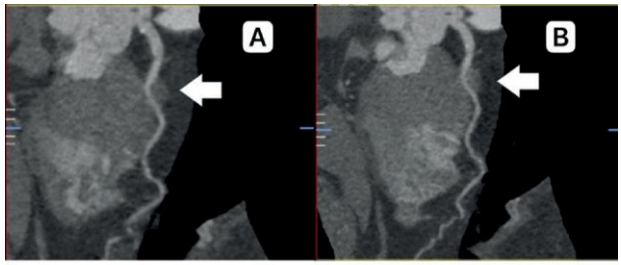

Figure 2. *A tunneled fragment and a pronounced myocardial bridge (arrows) in the systole (A) and diastole (B) in the proximal segment of the LAD (CT angiography of the coronary arteries).*

Рисунок 2. *Туннелированный фрагмент и выраженный миокардиальный мостик (стрелки) в систолу (А) и диастолу (В) в проксимальном сегменте ПМЖВ (КТ-КАГ).*

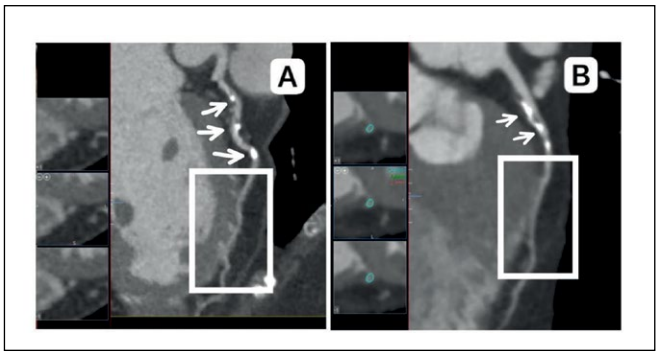

Figure 3. *A. The myocardial bridge in the distal third of the LAD (rectangle) with proximal atherosclerotic plaques (arrows). B. Myocardial bridge in the middle third of the LAD (rectangle) with proximal atherosclerotic plaques (arrows).*

Рисунок 3. *А. ММ в дистальной трети ПМЖВ (прямоугольник) с проксимальными атеросклеротическими бляшками (стрелки). В. ММ в средней трети ПМЖВ (прямоугольник) с проксимальными атеросклеротическими бляшками (стрелки).*

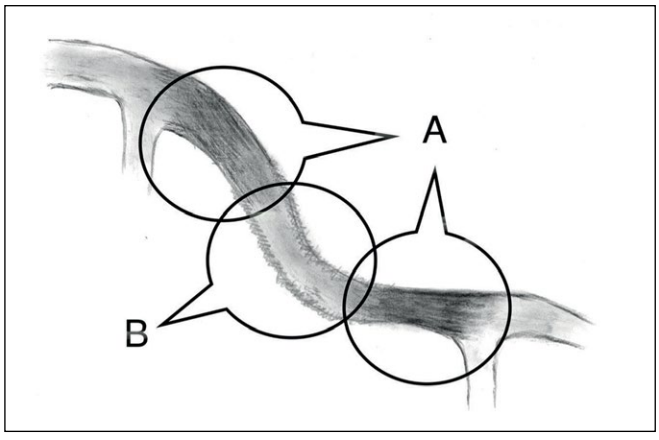

Figure 4. *Schematic representation of the relative profile of wall shear stress (WSS) during LAD angiography systole in a patient with MB. A: Segments located proximal and distal to MM demonstrate a relatively low WSS compared to the bridge segment (B).*

Рисунок 4. *Схематическое изображение относительного профиля напряжения сдвига стенки при ангиографии ПМЖВ во время систолы у пациента с ММ. А – сегменты, расположенные проксимальнее и дистальнее ММ, демонстрируют относительно низкое напряжение сдвига стенки по сравнению с мостовидным сегментом (В).*

myocardium. It was proven, however, that the systolic compression of the tunneled fragment of the coronary artery continues during the diastole as well, affecting the main phase of the coronary perfusion. Thus, the hemodynamic disorders are characterized with a persistent shrinkage of the diastolic diameter of the artery, increased blood flow velocity and the onset of the retrograde blood flow, which results in the decrease of the flow reserve. The diameter of the tunneled fragment of the coronary artery is not only less than that of the proximal segment of the vessel on the whole; moreover, during the diastole there is a persistent decrease of the intramural section by 34 to 51%. Furthermore, the greater the systolic stenosis, the lesser the diastolic diameter of the artery, which leads to the respective decrease of the blood flow and flow reserve [15]. Similar data was obtained in a different study: at the moment of diastolic contraction, the diameter of the coronary artery decreases by 80.6±9.2%, and the constant diastolic decrease is 35.3±11% in the tunneled fragment. The diastolic blood flow velocity in the bridge segment was much higher than that in the proximal and distal thereof [11]. The assessment of the fraction reserve proved to be an important tool for the physiological assessment of the MB. The researchers measured the fraction reserve both in the baseline condition and in the dobutamine stress test. Hemodynamic changes caused by the myocardial bridge were most manifested in the decrease of the diastolic fraction reserve (from 0.88 to 0.77), while the average value of the fraction reserve decreased to a lesser degree (from 0.90 to 0.84). It is considered that the average value of the fraction reserve is artificially skewed upwards due to peak systolic pressure; therefore, the preferred method of assessment is the diastolic fraction reserve [16].

Some studies involved multifactor analyses with consideration of the patients' age, diabetes and cardiomyopathy status credibly established a correlation of PAP and LAD, specifically, the presence of MB considerably increased the risk of coronary atherosclerosis [3, 4, 8, 11, 16–18]. In the proximal segment of the coronary artery, the atherosclerotic changes in the vessel wall are identified in 98% cases, and the segment of the MB itself never undergoes atherosclerotic changes, because the walls of the vessel lack the smooth muscle cells of the synthetic type, the ones that have the main role in the formation of the atherosclerotic plaque [19]. The higher pressure gradients in the arterial segments, located more proximally than the MB, may be the most powerful driver for the cholesterol to move to the endothelial layers when the patients demonstrate high cholesterol levels. The ingress of cholesterol, particles of lipoproteins of phagocytic cells may be identified as the 'inoculation effect' under high pressure gradient only in the proximal segment of the tunneled artery **(Fig. 3)**.

Lack of atherosclerosis in patients without hyperlipidemia may be the grounds for lowering the cholesterol levels in the blood serums using statins or by altering food habits and lifestyle to prevent further development of the atherosclerosis [4].

Some authors also think that MB could supposedly act as a protective factor against severe obstructive atherosclerosis in the entire coronary artery system with respect to the sex, age, diabetes status, hypertension and other risk factors [2, 16]. Some papers demonstrate mixed results precluding concrete results for this question [9, 12].

The microscopic inspection of the tunneled fragment of the coronary arteries found initial signs of the vascular wall lesion in 49% of cases in the form of fibrous-muscular dysplasia and lipidosis. The study using the results of CT-CAG failed to establish the cause and effect relation between the presence of MBs and atherosclerosis of the coronary arteries located subepicardially [15].

The rather contradictive data on the relation between the MB and PAP and on the possible protective effect of the tunneled fragment leave sufficient room for further research. The protective mechanism of the coronary artery mentioned by scientists is of special value: a more detailed study of this aspect may provide grounds for the development of methods of protection of the entire cardiovascular system from the adverse effects of atherogenesis.

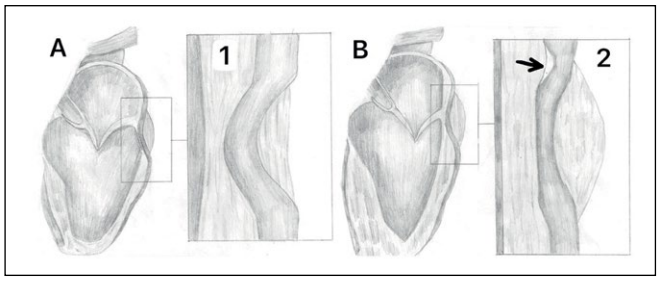

Figure 5. *A: Heart with MB, young age, early stage. 1: Longitudinal incision MB. B: Heart with MB, advanced age, advanced stage, with ventricular hypertrophy and diastolic dysfunction. 2: Longitudinal incision of MB with hypertrophied muscle and progressive proximal atherosclerotic plaque (arrow), negative remodeling of the vessel with a decrease in the diameter of the lumen.*

Рисунок 5. *А: Сердце с ММ, молодой возраст, ранняя стадия. 1 – продольный разрез ММ. В: Сердце с ММ, пожилой возраст, поздняя стадия, с гипертрофией желудочков и диастолической дисфункцией. 2 – продольный разрез ММ с гипертрофированной мышцей и прогрессирующей проксимальной атеросклеротической бляшкой (стрелка), негативное ремоделирование сосуда с уменьшением диаметра просвета.*

Hemodynamic mechanisms of the artery with a myocardia bridge are the main driver of proximal atherogenesis of the coronary artery. Models of computational fluid dynamics during the end of systole of the left coronary artery were used to demonstrate a rather low flow velocity in the proximal segment from the MB with a high flow velocity within the bridge **(Fig. 4)**.

The compression at the entry to the bridge results in a sharp cutoff of the antegrade systolic wave disturbing the flow structure, aggravating the low velocity of the flow, aggravating the endothelial lesion and stimulating the formation of atherosclerotic plaques [19]. Researchers also mention the importanc of effect of mechanical forces occurring due to the motion and deformation of the coronary bed. Systolic compression of the artery causes a turbulent blood flow and an increased vascular wall shear stress in the proximal segments thus stimulating the atherogenesis. Specifically, the compression within the bridge and the strong flexion of the vessel at the connection of the bridge with the intact proximal vascular wall result in a heterogeneous stressed condition in the proximal segment. It is suggested that this stressed condition contributes to the formation of plaques and the possible formation of cracks in the proximal segments [16].

Many studies point out that cardiac angina and heart rhythm disorders are registered more frequently in MB patients, as well as higher ACS and myocardial infarction risks [5–8, 11–14, 16, 19]; moreover, MBs may be the only known reason of the sudden cardiac death. At the same time, there are studies that do not identify any direct relation of MBs with the major adverse cardiovascular events [2, 10].

The findings of a large meta-analysis found no relation between the MB in the hypertrophic cardiomyopathy and the onset of non-fatal adverse cardiovascular events, but revealed a confirmed potential importance of their relation with the MI [20]. Development of clinically manifested cardiovascular diseases in patients with atherosclerotic lesion of the coronary artery might take several decades. The development of hypercholesterolemia and MB occur in the fourth and fifth decades of the patients' lives more frequently than in patients without MB [4].

In addition to the above mentioned mechanisms, life-long pathophysiological changes in the myocardium may cause MI symptoms in patients who had not earlier had any symptoms. Firstly, the increase of the diastolic function of the left ventricle related to age, hypertension and coronary atherosclerosis may aggravate the imbalance between the demand and supply of the blood perfusion caused by the presence of the bridge. Secondly, the development of hypertrophy of the left ventricle may increase the compression and decrease the coronary microvascular reserve **(Fig. 5)**.

Thirdly, the coronary angiospasm, microvascular or endothelial dysfunction related to cardiovascular risk factors, combined with the presence of the bridge, may result in the myocardial infarction. Fourthly, the formation of the plaques proximally to the bridge section may aggravate the coronary obstruction based by the bridge section. Finally, negative remodulation within the zone of the bridge section might reduce the blood flow in the myocardium. Each of these factors alone may foster development of symptoms in patients with tunneled segments in the myocardium to a lesser or greater extent [19]. The relation of MB with the symptoms of myocardial ischemia, lipidosis and different types of arrhythmia necessitates the search for new approaches towards early visualization of MB, especially in symptom-free patients, with the end of timely diagnostics of this pathology and prevention of cardiovascular complications that stem from it [21].

THERAPEUTIC METHODS

Despite the fact that the presence of a myocardial bridge may be related to such various complications as cardiac angina, acute myocardial infarction, arrhythmia and even sudden death, the myocardial bridge may be considered a positive outcome of the progress of coronary arteries. The necessity of treatment of MBs still causes doubt due to lack of solid evidence of their direct correlation with the manifestations of ACS. In clinical practice, β-blockers are usually drugs of first line of treatment of patients with symptoms likely related to MBs. Conservative approach (statins, β-blockers) is quite effective; however, refractory cases call for intervention and surgery treatment methods. Other therapeutic methods (coronary stents, myotomy, bypass surgery) are considered methods of the second and third order [2, 22].

Symptomatic patients are to be treated by conservative, intervention or surgical methods depending on their condition. The surgical procedure of choice to alleviate symptoms, improvement of coronary blood flow and decrease of compression of the coronary artery caused by the myocardial bridge is the myotomy [11, 13, 16, 19]. The choice of the surgery as the treatment method is complicated due the risk of development of restenosis, obstruction of the stent, and trauma of the myocardium. All CHD patients need cardiac rehabilitation procedures in accordance with the official recommendations and with respect to individual features, with strict supervision of hemodynamic parameters and ECG [22]. Patients with MB

and PAP require special attention due to the risk of ACS. The lack of clinical recommendations further complicates the choice of treatment.

Limitation of research: the majority of conducted studies are retrospective in nature and have no regard to genetic factors. Moreover, there are no long-term follow-up observations of PAP dynamics in the cases of MB.

Prospects of research. Firstly, long-term cohort studies focusing on PAP dynamics in cases of MB. Secondly, development of algorithms of risk stratification using AI and genetic markers. Thirdly, studies of the role of angular anatomy of coronary arteries and mechanisms of 'protection' of intramural segments from atherosclerosis.

CONCLUSION

Myocardial bridges are now recognized as a factor related to hemodynamic disorders, proximal atherosclerosis of the coronary artery, and myocardial infarction. Despite the protection of the intramural segment from atherosclerosis, the proximal segments are affected in 98% cases, and researchers relate this to the turbulent blood flow, endothelial dysfunction and high-pressure gradient, which contributes to the accumulation of lipids.

The sensitivity of MB diagnostic methods is varied: CT-CAG identifies up to 73% cases, while the selective endovascular coronary angiography identifies only 0.5 to 18%. Integration of functional methods (fractional flow reserve, induced stress tests) are required for the assessment of the hemodynamic significance of MB and stratification of risk. The data on the correlation of MB with cardiac angina, ACS and sudden cardiac death remain disputable: while some studies deny direct correlation, others emphasize the role of MB as the trigger of ischemia, especially on the background of myocardial hypertrophy, age-related diastolic dysfunction or microvascular disorders.

Conservative therapy (β-blockers, statins) demonstrates some efficiency; however, refractory forms require invasive therapy (stenting, myotomy). The lack of randomized studies restricts the formation of universal recommendations. Myocardial bridges necessitate revision of diagnostic and therapeutic approaches. The key areas of optimization of management of patients with this anomaly are the integration of morphological and functional visualization as well as personalization of treatment based on the individual risk of ischemia and atherosclerosis.

ADDITIONAL INFORMATION	ДОПОЛНИТЕЛЬНАЯ ИНФОРМАЦИЯ
Ethics approval: Not applicable.	***Этическая экспертиза.*** Неприменимо.
Study funding. The study was the authors' initiative without external funding.	***Источник финансирования.*** Работа выполнена по инициативе авторов без привлечения финансирования.
Conflict of interest. The authors declare that there are no obvious or potential conflicts of interest associated with the content of this article.	***Конфликт интересов.*** Авторы декларируют отсутствие явных и потенциальных конфликтов интересов, связанных с содержанием настоящей статьи.
Contribution of individual authors. Kolyan B.Yu.: idea, literature search, writing of the text. Margaryan A.V., Chemidrov S.N.: scientific supervision, editing of the manuscript. All authors gave their final approval of the manuscript for submission, and agreed to be accountable for all aspects of the work, implying proper study and resolution of issues related to the accuracy or integrity of any part of the work.	***Участие авторов.*** Колян Б.Ю. – идея, поиск литературы, написание текста. Маргарян А.В., Чемидров С.Н. – научное руководство, редактирование рукописи. Все авторы одобрили финальную версию статьи перед публикацией, выразили согласие нести ответственность за все аспекты работы, подразумевающую надлежащее изучение и решение вопросов, связанных с точностью или добросовестностью любой части работы.
Statement of originality. No previously published material (text, images, or data) was used in this work.	***Оригинальность.*** При создании настоящей работы авторы не использовали ранее опубликованные сведения (текст, иллюстрации, данные).
Data availability statement. The editorial policy regarding data sharing does not apply to this work.	***Доступ к данным.*** Редакционная политика в отношении совместного использования данных к настоящей работе не применима.
Generative AI. No generative artificial intelligence technologies were used to prepare this article.	***Генеративный искусственный интеллект.*** При создании настоящей статьи технологии генеративного искусственного интеллекта не использовали.
Provenance and peer review. This paper was submitted unsolicited and reviewed following the standard procedure. The peer review process involved 2 external reviewers.	***Рассмотрение и рецензирование.*** Настоящая работа подана в журнал в инициативном порядке и рассмотрена по обычной процедуре. В рецензировании участвовали 2 внешних рецензента.

REFERENCES / ЛИТЕРАТУРА

1. Bagmanova ZA. Myocardial bridges of coronary arteries. *Cardiovascular therapy and prevention*. 2007;6(6):125-130. (In Russ.). [Багманова З.А. Миокардиальные мостики коронарных артерий. Кардиоваскулярная терапия и профилактика. 2007;6(6):125-130]. URL: https://elibrary.ru/item.asp?id=9956630 EDN: IJWXLB

2. Jiang L, Zhang M, Zhang H, et al. A potential protective element of myocardial bridge against severe obstructive atherosclerosis in the whole coronary system. *BMC Cardiovascular Disorders*. 2018;18(1):105. DOI: 10.1186/s12872-018-0847-8

3. Nakaura T, Nagayoshi Y, Awai K, et al. Myocardial bridging is associated with coronary atherosclerosis in the segment proximal to the site of bridging. *Journal of Cardiology*. 2014;63(2):134-139. DOI: 10.1016/j.jjcc.2013.07.005

4. Aparci M, Ozturk C, Balta S, et al. Hypercholesterolemia is Accounted for Atherosclerosis at the Proximal Arterial Segments of Myocardial Bridging: A Pilot Study. *Clinical and Applied Thrombosis/Hemostasis*. 2016;22(3):297-302. DOI: 10.1177/1076029614554995

5. Micic-Labudovic J, Atanasijevic T, Popovic V, et al. Myocardial bridges: a prospective forensic autopsy study. *Srpski Arhiv za Celokupno Lekarstvo*. 2015;143(3-4):153-157. DOI: 10.2298/sarh1504153m

6. Lucena JD, Brito HM, Sanders JVS, et al. Incidence and Morphological Study of Myocardial Bridge in the State of Ceará: A Cadaveric Study. *Arquivos Brasileiros de Cardiologia*. 2023;120(7):e20220460. DOI: 10.36660/abc.20220460

7. Alsoufi B. Do not miss the bridge. *The Journal of Thoracic and Cardiovascular Surgery*. 2018;156(4):1627-1628. DOI: 10.1016/j.jtcvs.2018.02.082

8. Ishii T, Hosoda Y, Osaka T, et al. The significance of myocardial bridge upon atherosclerosis in the left anterior descending coronary artery. *The Journal of Pathology*. 1986;148(4):279-291. DOI: 10.1002/path.1711480404

9. Hostiuc S, Negoi I, Rusu MC, et al. Myocardial Bridging: A Meta-Analysis of Prevalence. *Journal of Forensic Sciences*. 2018;63(4):1176-1185. DOI: 10.1111/1556-4029.13722

10. Hong L, Liu J, Luo S, Li J. Relation of myocardial bridge to myocardial infarction: a meta-analysis. *Chinese Medical Journal*. 2014;127(5):945-950. PMID: 24571892

11. Yuan SM. Myocardial Bridging. *Brazilian Journal of Cardiovascular Surgery*. 2016;31(1):60-62. DOI: 10.5935/1678-9741.20150082

12. Starodubov OD, Efremova OA, Obolonkova NI, et al. Myocardial Bridges: Pathophysiology, Mechanisms of Atherosclerosis Development, Modern Diagnostic and Treatment Approaches (Literature Review). *Modern science: actual problems of theory and practice. Series: Natural and Technical Sciences*. 2023;7:208-214. [Стародубов О.Д., Ефремова О.А., Оболонкова Н.И., и др. Миокардиальные мышечные мостики: патофизиология, механизмы развития атеросклероза, современная тактика диагностики и лечения (литературный обзор). Современная наука: актуальные проблемы теории и практики. Серия: Естественные и технические науки. 2023;7:208-214]. DOI: 10.37882/2223-2982.2023.07.38

13. Zhalilov AK, Vishchipanov AS, Akhmatov YaR. Acute coronary syndrome caused by the myocardial bridge. *Modern science: actual problems of theory and practice. Series: Natural and Technical Sciences*. 2023;7-2:218-221. [Жалилов А.К., Вищипанов А.С., Ахматов Я.Р. Острый коронарный синдром, обусловленный миокардиальным мостиком. Современная наука: актуальные проблемы теории и практики. Серия: Естественные и технические науки. 2023;7-2:218-221]. DOI: 10.37882/2223-2982.2023.7-2.12

14. Jiang X, Zhou P, Wen C, et al. Coronary Anomalies in 11,267 Southwest Chinese Patients Determined by Angiography. *Biomed Res Int*. 2021:6693784. DOI: 10.1155/2021/6693784

15. Kabak SL, Melnichenko YuM, Gordionok DM, et al. Myocardial bridges and obstructive atherosclerosis of the coronary arteries. *Weight of the National Academy of Sciences of Belarus*. 2020;17(1):38-48. [Кабак С.Л., Мельниченко Ю.М., Гордионок Д.М., и др. Миокардиальные мостики и обструктивный атеросклероз венечных артерий. Весці Нацыянальнай акадэміі навук Беларусі. 2020;17(1):38-48]. DOI: 10.29235/1814-6023-2020-17-1-38-48

16. Lee MS, Chen CH. Myocardial Bridging: An Up-to-Date Review. *The Journal of Invasive Cardiology*. 2015;27(11):521-528. PMCID: PMC4818117

17. Tian SP, Li CP, Song X, et al. Association of myocardial bridge of the left anterior descending coronary artery with coronary atherosclerotic stenosis in the segment proximal to the site of bridge. *Acta Academiae Medicinae Sinicae*. 2014;36(2):153-157. DOI: 10.3881/j.issn.1000-503X.2014.02.007

18. Hong H, Wang MS, Liu Q, et al. Angiographically evident atherosclerotic stenosis associated with myocardial bridging and risk factors for the artery stenosis located proximally to myocardial bridging. *Anatolian Journal of Cardiology*. 2014;14(1):40-47. DOI: 10.5152/akd.2013.4702

19. Corban MT, Hung OY, Eshtehardi P, et al. Myocardial bridging: contemporary understanding of pathophysiology with implications for diagnostic and therapeutic strategies. *Journal of the American College of Cardiology*. 2014;63(22):2346-2355. DOI: 10.1016/j.jacc.2014.01.049

20. Bruce C, Ubhi N, McKeegan P, Sanders K. Systematic Review and Meta-Analysis of Cardiovascular Consequences of Myocardial Bridging in Hypertrophic Cardiomyopathy. *The American Journal of Cardiology*. 2023;188:110-119. DOI: 10.1016/j.amjcard.2022.10.059

21. Mirzoev NT, Shulenin KS, Kutelev GG, et al. Prevalence, Anatomic-Topographic Features and Clinical Significance of Myocardial Bridges: a Retrospective Study. *Doctor.ru*. 2023;22(8):17-22. [Мирзоев Н.Т., Шуленин К.С., Кутелев Г.Г., и др. Распространенность, анатомо-топографические особенности и клиническое значение миокардиальных «мостиков»: ретроспективное исследование. Доктор.Ру. 2023;22(8):17-22]. DOI: 10.31550/1727-2378-2023-22-8-17-22

22. Sizov AV, Gornov SV, Matyushevsky IV, et al. Myocardial muscular bridge, issues of diagnosis, treatment and medical rehabilitation on the example of a specific clinical case. *Medical Alliance*. 2023;11(4):119-128. [Сизов А.В., Горнов С.В., Матюшевский И.В., и др. Миокардиальный мышечный мостик, вопросы диагностики, лечения и медицинской реабилитации на примере конкретного клинического случая. Медицинский альянс. 2023;11(4):119-128]. DOI: https://doi.org/10.36422/23076348-2023-11-4-119-128