



Case Report | Клинический случай
DOI: <https://doi.org/10.35693/SIM680158>

This work is licensed under CC BY 4.0
© Authors, 2025

Surgical treatment of patient with osteomyelitis of the hip using preoperative 3D modeling and “Autoplan” software suite

Igor V. Makarov, Sergei V. Ladonin, Darya A. Bondareva
Samara State Medical University (Samara, Russian Federation)

Abstract

The article presents a clinical case of treatment of a patient with chronic post-traumatic osteomyelitis of the femur. A fundamentally important point was the analysis of the CT scan results in the Autoplan hardware and software complex (APC) system according to the developed method and the construction of a 3D model of the lower extremities. As a result, the osteomyelitis focus was visualized. Based on the 3D model and using the intraoperative navigation

of the “Autoplan” software suite, the patient underwent a femoral sequesterectomy. The assessment of the immediate and long-term treatment results was carried out.

Keywords: osteomyelitis, 3D modeling, sequesterectomy, intraoperative navigation.

Conflict of interest: nothing to disclose.

Citation

Makarov IV, Ladonin SV, Bondareva DA. **Surgical treatment of patient with osteomyelitis of the hip using preoperative 3D modeling and “Autoplan” software suite.** *Science and Innovations in Medicine.* 2026;11(1):77-82. DOI: <https://doi.org/10.35693/SIM680158>

Information about authors

***Igor V. Makarov** – MD, Dr. Sci. (Medicine), Professor, Head of the Department of General Surgery and Surgical Diseases. ORCID: <https://orcid.org/0000-0002-1068-3330>
E-mail: i.v.makarov@samsmu.ru

Sergei V. Ladonin – MD, Cand. Sci. (Medicine), Associate professor of the Department of General Surgery and Surgical Diseases, Head of the Surgical Department No.2 of the Clinic of Propaedeutic Surgery. ORCID: <https://orcid.org/0000-0002-0028-503X>
E-mail: s.v.ladonin@samsmu.ru

Darya A. Bondareva – MD, assistant of the Department of General Surgery and Surgical Diseases, surgeon of the Surgical Department No.2 of the Clinic of Propaedeutic Surgery. ORCID: <https://orcid.org/0009-0003-4003-0765>
E-mail: d.a.holodkova@samsmu.ru

*Corresponding Author

Received: 22.05.2025
Accepted: 08.07.2025
Published: 17.10.2025

Хирургическое лечение пациента с остеомиелитом бедренной кости с использованием предоперационного 3D-моделирования и аппаратно-программного комплекса «Автоплан»

И.В. Макаров, С.В. Ладонин, Д.А. Бондарева

ФГБОУ ВО «Самарский государственный медицинский университет» Минздрава России
(Самара, Российская Федерация)

Аннотация

Представлен клинический случай лечения пациента с хроническим посттравматическим остеомиелитом бедренной кости. Принципиально важным моментом стал анализ результатов КТ-исследования в системе аппаратно-программного комплекса (АПК) «Автоплан» по разработанному способу и построение 3D-модели нижних конечностей. В результате был визуализирован очаг остеомиелита. На основе 3D-модели и интра-

операционной навигации АПК «Автоплан» пациенту была выполнена секвестрэктомия бедренной кости. Произведена оценка ближайших и отдаленных результатов лечения.

Ключевые слова: остеомиелит, 3D-моделирование, секвестрэктомия, интраоперационная навигация.

Конфликт интересов: не заявлен.

Для цитирования:

Макаров И.В., Ладонин С.В., Бондарева Д.А. **Хирургическое лечение пациента с остеомиелитом бедренной кости с использованием предоперационного 3D-моделирования и аппаратно-программного комплекса «Автоплан».** *Наука и инновации в медицине.* 2026;11(1):77-82. DOI: <https://doi.org/10.35693/SIM680158>

Сведения об авторах

***Макаров Игорь Валерьевич** – д-р мед. наук, профессор, заведующий кафедрой общей хирургии и хирургических болезней. ORCID: <https://orcid.org/0000-0002-1068-3330>
E-mail: i.v.makarov@samsmu.ru
Ладонин С.В. – канд. мед. наук, доцент кафедры общей хирургии и хирургических болезней, заведующий хирургическим отделением №2 Клиники пропедевтической хирургии.

ORCID: <https://orcid.org/0000-0002-0028-503X>

E-mail: s.v.ladonin@samsmu.ru
Бондарева Д.А. – ассистент кафедры общей хирургии и хирургических болезней, врач-хирург хирургического отделения №2 Клиники пропедевтической хирургии. ORCID: <https://orcid.org/0009-0003-4003-0765>
E-mail: d.a.holodkova@samsmu.ru

*Автор для переписки

Получено: 22.05.2025
Одобрено: 08.07.2025
Опубликовано: 17.10.2025

■ BACKGROUND

Osteomyelitis is a purulent-inflammatory disease affecting all bone elements and adjacent soft-tissue structures, leading to deformity and functional impairment in organs and body systems [1–5]. Among all purulent and septic diseases, osteomyelitis accounts for 6.8–12%, and in 3–5% cases, the disease is the cause of damage to the locomotion apparatus [6].

Chronic osteomyelitis is considered an incurable disease due to its severe and long-term progression, complicated treatment and development of complications. Despite the strong technological progress, implementation of new pathogenic approaches towards treatment of the disease with consideration of etiological factors, the outcomes of treatment leave room for improvement. The recurrence rate within one year is at least 30% of all post-surgery patients, with 42.1% to 74.3% in remote periods. The patients require multiple surgeries [5, 7]. The success of treatment largely depends on the radicality of the operation and adequate sanitation of the focus of the infection. Use of preoperative 3D-modeling and intraoperative navigation is highly instrumental in the efficacy of surgical treatment.

We propose a clinical study that enables evaluation of surgical tactics and long-term outcomes of treatment of the patient with osteomyelitis of the femur, in which preoperative 3D-modeling and software and hardware suite Autoplan were used.

■ CASE DESCRIPTION

Patient M., aged 71, was admitted to the department of surgery on March 25, 2024. The patient considers his disease to date back to 2004, when in a traffic accident he had a closed displaced fracture of the medium third of the left femur. He underwent an intramedullary nailing. One month after the operation, despite the marked tendency for the fracture union, there appeared a fistula opening on the left hip. Three months after the operation, a follow-up X-ray examination was performed showing consolidation of the fracture, and the nail was removed. In 2010, the patient underwent an operation for osteomyelitis

of the left femur, and sequestrectomy was performed, following which clinical healing was reported with lack of infection process in the injury area. In 2024, the fistula reappeared. The patient himself put bandages using wet-to-dry dressings with aqueous solutions of antiseptics (Mestamidin, Chloroxehidine) and salve dressings (Levomecol, Oflomelid), with no positive dynamics. The patient received outpatient consultations of the surgeon and was recommended planned surgical treatment.

On admission, the patient underwent a standard examination including total blood count, clinical urine analysis, blood coagulation test, biochemical blood test, microbiology examination of the wound fluid for susceptibility to antibiotics, as well as X-ray examination of the right femur.

The examination found that the patient had multiple postoperative scars on the hip, and on the anteriomedial and lateral surface there were two fistula openings up to 1.0 cm in diameter with moderate purulent discharge (up to 5 mL per day). The revision of the fistulas with a bulb-headed probe, the end of the probe touched the femoral bone. Both active and passive movement in the knee and hip joint were preserved. Pulsation of the main arteries was satisfactory; the sensitivity was preserved.

The microbiological examination of the wound fluid identified *Pseudomonas aeruginosa* 105. Following the antibiotic susceptibility pattern, the patient was prescribed respective etiological antimicrobial therapy.

In the preoperative preparation phase, a CT scan of the lower extremities was performed (**Fig. 1**). The series of CT scans in the multi-plane and 3D projections periosteal layering was observed in the lower third of the femoral shaft, accompanied by focal disruption of the cortical layer. In the upper and medium thirds, bone expansion was visualized, the cortical layers were sclerotized and deformed; there were areas of periosteal reaction on the lateral surface of the femoral bone. The fistula tract was identified at the level of the middle third of the thigh, extending up to 20 mm to the lateral surface. Additionally, formation of the fistula tract at the level

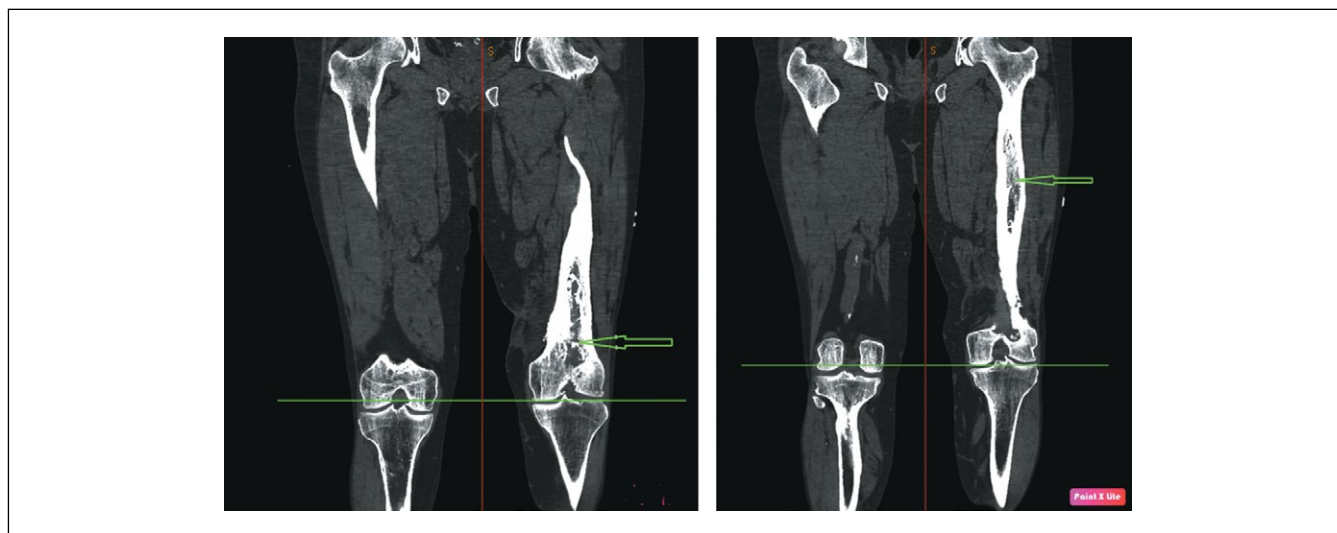


Figure 1. CT scan of the lower extremities, frontal projection. Arrows indicate the osteomyelitis focus.

Рисунок 1. КТ нижних конечностей, фронтальная проекция. Стрелками указан очаг остеомиелита.

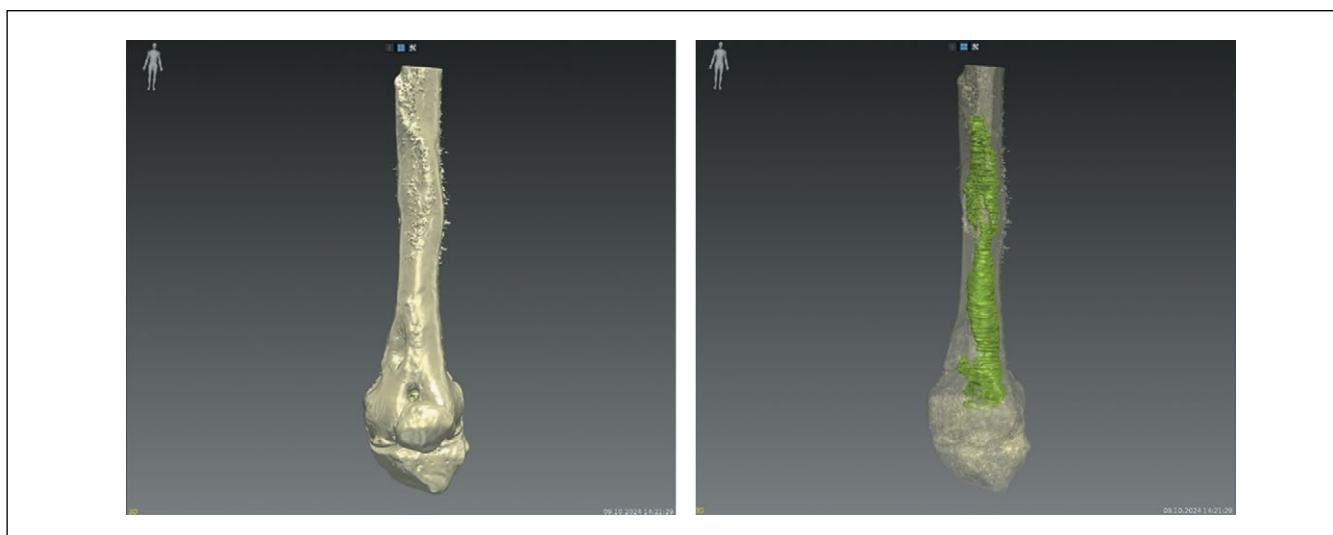


Figure 2. 3D model of the femur based on the CT scan. The osteomyelitis lesion is shown in green.

Рисунок 2. 3D-модель бедренной кости на основе КТ-исследования. Зеленым цветом обозначен очаг остеомиелита.

of the lower third, extending to the medial surface of the thigh, was noted.

Based on the CT examination, a 3D-model of the femoral bone was built visualizing the focus of osteomyelitis¹. DICOM data was uploaded to Autoplan, and the following transformations were performed: 1) alignment of separate CT scan series to a unified coordinate system; 2) segmentation (marking) of boundaries of anatomical structures on the images; 3) construction of three-dimensional polygonal models based on the segmented boundaries of anatomical structures (**Fig. 2**).

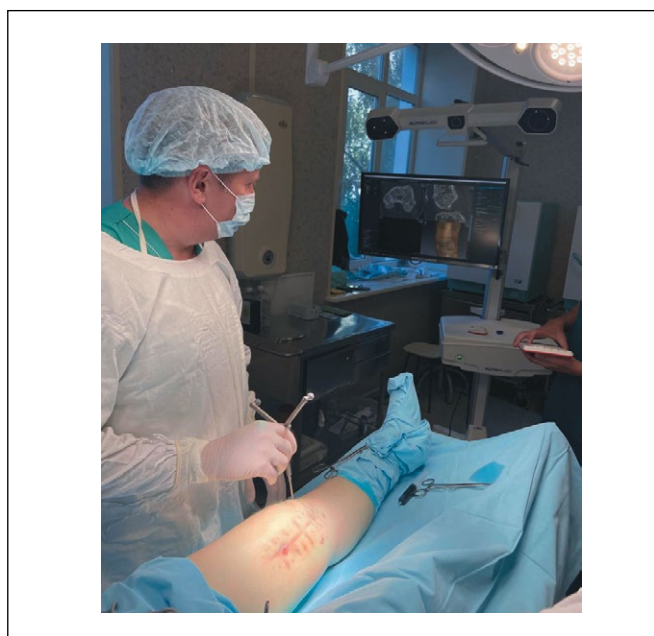


Figure 3. Combining the position of a virtual model of the osteomyelitis focus with its real location into a single coordinate system using the Autoplan APCS and a pointer with reflective markers.

Рисунок 3. Совмещение положения виртуальной модели очага остеомиелита с его реальным расположением в единую систему координат с использованием АПК «Автоплан» и указки со светоотражающими маркерами.

In order to reconstruct the shape of anatomical objects between the visible scans, 2D and 3D interpolation algorithms were used. 3D polygonal models of the finest anatomical structures were constructed without smoothing, while surface smoothing was applied to models of larger anatomical structures. For each model, the color and transparency degree were chosen to ensure the informative value of the entire three-dimensional scene.

On the surgical field, prior to skin incision, anatomical guides were chosen (in this case, the upper and the lower, medial and distal edges of the kneecap, and femoral condyles), on which the anchor points were marked that were fixed on the virtual model using a special pointer with light-reflective markers. At the same time, the virtual model of the focus of osteomyelitis was aligned with its actual position in this patient in the single coordinate system. After that, it became possible to visualize the virtual model of the hip bone with the focus of osteomyelitis and the pointer on the screen in real time. By moving the pointer in the points of the topical

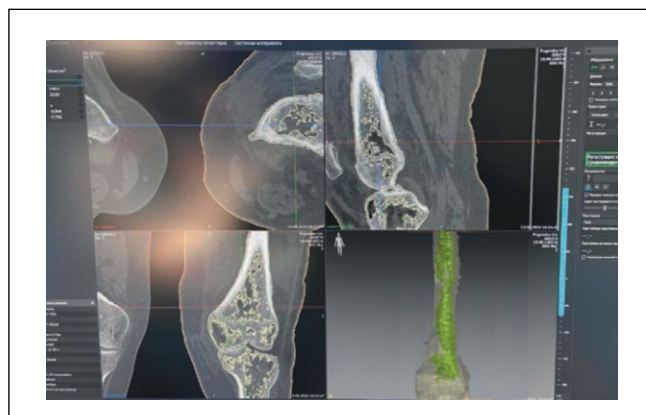


Figure 4. Computed tomography of the femur with the focus of osteomyelitis and the 3D model.

Рисунок 4. Компьютерная томография бедренной кости с очагом остеомиелита и 3D-модель.

¹ Filing receipt No.2025107993 for the invention "Method of topical diagnostics and visualization of lesion of osseous tissue destruction in chronic osteomyelitis of long tubular bones" dated 21.02.2025.

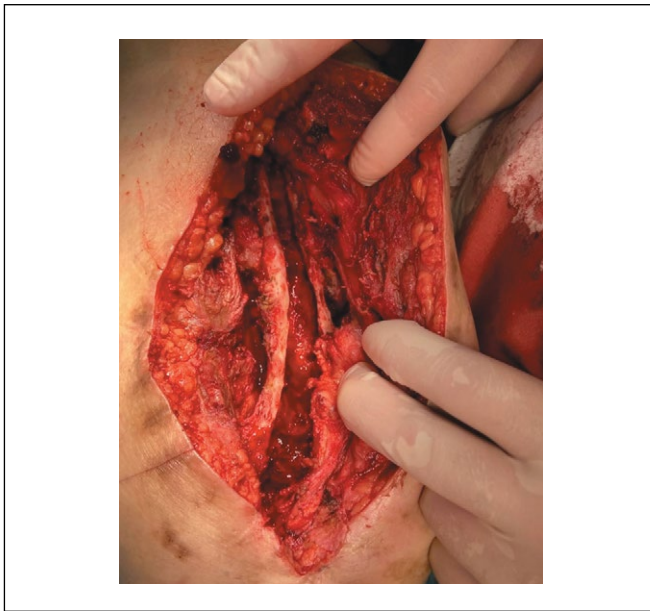


Figure 5. Bone cavity after sanitation of the osteomyelitis focus.
Рисунок 5. Костная полость после санации очага остеомиелита.

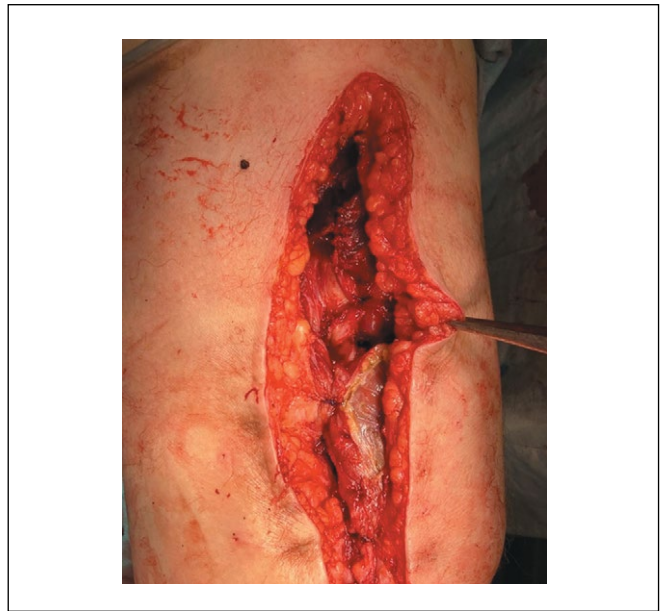

Figure 6. Bone cavity closure with a pedicled muscle flap.
Рисунок 6. Пластика костной полости мышцей на питающей ножке.

position of the focus of osteomyelitis and referring its position with intact sections of the bone, the access to the focus of pathology was selected, and its actual localization was found during the surgery with consideration of the patient's individual anatomic features (**Fig. 3, 4**).

After delineating the osteomyelitic focus boundaries, sequestrectomy of the femoral bone was performed. The fistula opening on the anteromedial surface of the left thigh was excised. Infected tissues and pathological granulations were removed. The wound was closed with sutures. Converging incisions up to 15 cm long, incorporating excision of the fistula opening on the lateral surface of the left thigh, were made to dissect the soft tissues down to the bone. The eroded femoral bone was exposed. The periosteum was elevated with a periosteal elevator. Using a chisel and mallet, trepanation of the femoral bone was performed along the entire extent of the lesion, guided by the 3D model. A 15 cm long cavity was created (**Fig. 5**). Curettage was performed with a Volkman spoon until punctate bleeding was achieved. Antiseptic lavage with Mestamidin was performed, followed by plasty of the bone cavity using a portion of the quadriceps femoris muscle on a distal pedicle (**Fig. 6**). The wound was closed in layers.

The postoperative period had no complications. The wound healed by primary intention. The stitches were removed on day 8 after the surgery (**Fig. 7**). The patient was discharged in a satisfactory condition to be followed up by a surgeon in the local medical facility.

Follow-up examinations were performed in 1, 3, and 6 months from the operation. No wound defects, fistula openings, pain at rest or in motion, no restrictions under exercise were seen.

The quality of life was analyzed using the questionnaire specifically developed for patients operated for chronic osteomyelitis. It is an enhanced international questionnaire to assess quality of life SF-36 (HEALTH STATUS SURVEY). The changes were observed in the value of

pain intensity: before the surgery, it was 38%, after the surgery, 100%. This shows that the sensation of pain was practically relieved and did not restrict the patient's activity. The value of vitality increased twofold. The value of 'social functioning' domain increased from 62.5 to 95.5%, i.e. by 33%; therefore, the patients physical and emotional condition had less limitations on their capability and desire to communicate. The value on the 'mental health' domain increased by 56%, a significant improvement of the patient's mental status.

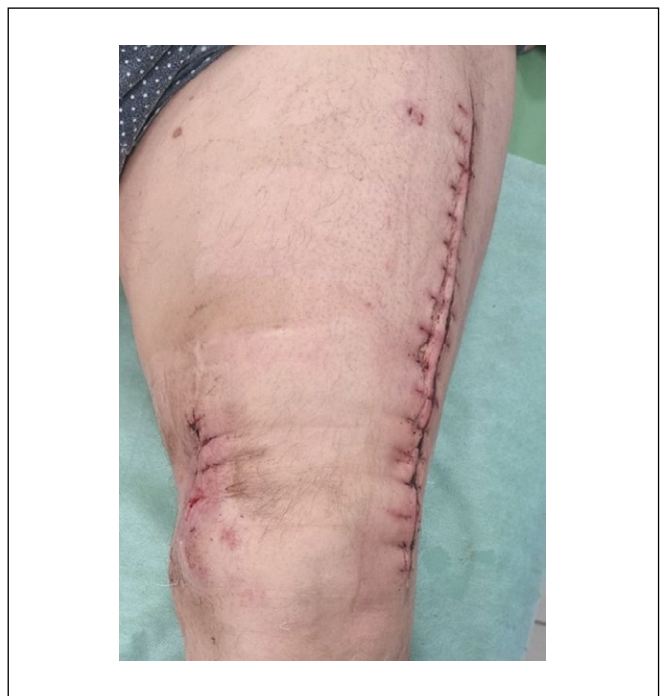

Figure 7. Photo of the lower limb of patient M., 71 years old, 8 days after surgery.

Рисунок 7. Фото нижней конечности пациента М., 71 года, на 8 сутки после оперативного вмешательства.

The physical and mental components of health status were also calculated. Before the surgery, the physical component was 36.1%, after the surgery, 55.6%: an increase by 19.5%. The mental component of health status before the surgery was 29.3%, after the surgery, 73.1%: an increase by 43.8%.

DISCUSSION

Treatment of patients with osteomyelitis of long tubular bones is a most complex challenge of purulent surgery. The problem of chronic osteomyelitis remains vital not only due to difficulties of its diagnostics, treatment and prevention, but also due to high costs of patient treatment, long-term incapacity to work, high incidence of disablement, which, according to Russian authors, is 55–65%, and, according to foreign authors, may reach 90% [8–10].

Sequestrectomy became the most significant of radical surgical interventions in the treatment of osteomyelitis [11].

Currently, clinical practice places significant emphasis on the application of a personalized approach, innovative imaging modalities, and preoperative surgical planning. One of perspective areas is the preoperative 3D-modeling based on CT examination and intraoperative navigation

using the Autoplan¹ hardware and software complex [12]. For the surgical treatment of osteomyelitis, this method provides precise visualization of the pathological focus, determination of its boundaries before and during the surgery based on individual anthropometric data of each patient [13, 14]. The use of the personalized approach allows for reduction of surgery time, maximum preservation of intact bone tissue, and the best aesthetic outcome [15].

CONCLUSION

The use of preoperative 3D-modeling and intraoperative navigation with the Autoplan hardware and software complex in sequestrectomy allows for a radical excision of the focus of infection, preservation of a maximum amount of healthy soft and bony tissue, and achievement of osteomyelitis remission.

An individualized approach to the patient, accounting for their anatomical specificities, combined with the correctly chosen treatment strategy, yielded favorable short- and long-term outcomes while preserving quality of life. The 6-month postoperative follow-up of our patient revealed improved quality of life and no disease recurrence, confirming the high efficacy of the method. ■

| ADDITIONAL INFORMATION | ДОПОЛНИТЕЛЬНАЯ ИНФОРМАЦИЯ |
|---|--|
| Study funding. The study was the authors' initiative without external funding. | Источник финансирования. Работа выполнена по инициативе авторов без привлечения финансирования. |
| Conflict of interest. The authors declare that there are no obvious or potential conflicts of interest associated with the content of this article. | Конфликт интересов. Авторы декларируют отсутствие явных и потенциальных конфликтов интересов, связанных с содержанием настоящей статьи. |
| Contribution of individual authors. Makarov I.V.: concept and design of the study, analysis and interpretation of data, editing of the article. Ladonin S.V.: writing of the text and its editing. Bondareva D.A.: writing of the text. All authors gave their final approval of the manuscript for submission, and agreed to be accountable for all aspects of the work, implying proper study and resolution of issues related to the accuracy or integrity of any part of the work. | Участие авторов. Макаров И.В. – концепция и дизайн исследования, анализ и интерпретация данных, редактирование статьи. Ладонин С.В. – написание текста и его редактирование. Бондарева Д.А. – написание текста. Все авторы одобрили финальную версию статьи перед публикацией, выразили согласие нести ответственность за все аспекты работы, подразумевающую надлежащее изучение и решение вопросов, связанных с точностью или добросовестностью любой части работы. |
| Consent for publication. Written consent was obtained from the patient for the depersonalized publication of relevant medical information and all of accompanying images in the journal. | Информированное согласие на публикацию. Авторы получили письменное согласие пациента на публикацию в журнале медицинских данных и фотографий в обезличенной форме. |
| Statement of originality. No previously published material (text, images, or data) was used in this work. | Оригинальность. При создании настоящей работы авторы не использовали ранее опубликованные сведения (текст, иллюстрации, данные). |
| Data availability statement. The editorial policy regarding data sharing does not apply to this work. | Доступ к данным. Редакционная политика в отношении совместного использования данных к настоящей работе не применима. |
| Generative AI. No generative artificial intelligence technologies were used to prepare this article. | Генеративный искусственный интеллект. При создании настоящей статьи технологии генеративного искусственного интеллекта не использовали. |
| Provenance and peer review. This paper was submitted unsolicited and reviewed following the standard procedure. The peer review process involved 2 external reviewers. | Рассмотрение и рецензирование. Настоящая работа подана в журнал в инициативном порядке и рассмотрена по обычной процедуре. В рецензировании участвовали 2 внешних рецензента. |

REFERENCES / ЛИТЕРАТУРА

- Kotelnikov GP, Mironov SP. *Traumatology: National Guidelines*. М., 2011. (In Russ.). [Котельников Г.П., Миронов С.П. *Травматология: национальное руководство*. М., 2011].
- Calhoun JH, Manring MM, Shirliff M. Osteomyelitis of the long bones. *Semin Plast Surg*. 2009;23(2):59-72. DOI: 10.1055/s-0029-1214158
- Conterno LO, da Silva Filho CR. Antibiotics for treating chronic osteomyelitis in adults. *Cochrane Database Syst Rev*. 2009;3:CD004439. DOI: 10.1002/14651858.CD004439.pub3
- Hotchen AJ, McNally MA, Sendi P. The Classification of Long Bone Osteomyelitis: A Systemic Review of the Literature. *Journal of Bone and Joint Infection*. 2017;2(4):167-174. DOI: 10.7150/jbji.21050

¹ Patent of the Russian Federation for the invention No. 2683743. Makarov V.I., Kolsanov A.V., Zhirov V.V. et al. "Method of topical diagnostics and visualization of adenomas of the parathyroid in secondary and tertiary hyperparathyrosis". URL: <https://patents.google.com/patent/RU2683743C1/ru>

5. Kolinsky DC, Liang SY. Musculoskeletal Infections in the Emergency Department. *Emergency Medicine Clinics of North America*. 2018;36(4):751-766. DOI: [10.1016/j.emc.2018.06.006](https://doi.org/10.1016/j.emc.2018.06.006)
6. Rimashevskiy DV, Akhtyamov IF, Fedulichev PN. Interdisciplinary approach to diagnostics and treatment osteomyelitis. *Practical medicine. Практическая медицина*. 2021;19(1):54-61. [Римашевский Д.В., Ахтямов И.Ф., Федуличев П.Н. Междисциплинарный подход к диагностике и лечению остеомиелита. *Практическая медицина*. 2021;19(1):54-61]. URL: <https://pmarchive.ru/mezhdisciplinarnyj-podxod-k-diaagnostike-i-lecheniyu-osteomielita/>
7. Mikulich EV. Current principles of treatment of chronic osteomyelitis. *Journal of New Medical Technologies*. 2012;19(2):180-184. [Микулич Е.В. Современные принципы лечения хронического остеомиелита. *Вестник новых медицинских технологий*. 2012;19(2):180-184]. URL: <https://cyberleninka.ru/article/n/sovremennye-printsipy-lecheniya-hronicheskogo-osteomielita>
8. Mironov SP, Tsiskarashvili AV, Gorbatiuk DS. Chronic post-traumatic osteomyelitis as a problem of contemporary traumatology and orthopedics (literature review). *Genij Ortopedii*. 2019;25(4):610-621. [Миронов С.П., Цискарашвили А.В., Горбатиук Д.С. Хронический посттравматический остеомиелит как проблема современной травматологии и ортопедии (обзор литературы). *Гений ортопедии*. 2019;25(4):610-621]. DOI: [10.18019/1028-4427-2019-25-4-610-621](https://doi.org/10.18019/1028-4427-2019-25-4-610-621)
9. Campana V, Milano G, Pagano E, et al. Bone substitutes in orthopaedic surgery: from basic science to clinical practice. *J Mater Sci Mater Med*. 2014;25(10):2445-2461. DOI: [10.1007/s10856-014-5240-2](https://doi.org/10.1007/s10856-014-5240-2)
10. Humm G, Noor S, Bridgeman P, et al. Adjuvant treatment of chronic osteomyelitis of the tibia following exogenous trauma using OSTEOSSET-T: a review of 21 patients in a regional trauma 177 centre. *Strategies Trauma Limb Reconstr*. 2014;9(3):157-161. DOI: [10.1007/s11751-014-0206-y](https://doi.org/10.1007/s11751-014-0206-y)
11. Chaklin VD. *Fundamentals of operative orthopedics and traumatology*. М., 1964. (In Russ.). [Чаклин В.Д. *Основы оперативной ортопедии и травматологии*. М., 1964].
12. Ivashkov VYu, Denisenko AS, Kolsanov AV, et al. Maxillary reconstruction using the "Autoplan" software suite. *Plastic Surgery and Aesthetic Medicine*. 2024;(4-2):58-65. [Ивашков В.Ю., Денисенко А.С., Колсанов А.В., и др. Устранение дефектов нижней челюсти с применением программного комплекса «Автоплан». *Пластическая хирургия и эстетическая медицина*. 2024;(4-2):58-65. DOI: [10.17116/plast.hirurgia202404258](https://doi.org/10.17116/plast.hirurgia202404258)
13. Zhao J, Wang Z, Long C, et al. Using 3-D printing-assisted shaping titanium cages and Masquelet techniques to reconstruct calcaneal osteomyelitis complicated by extensive 301 soft tissue and uncontrolled defects. *Injury*. 2023;54(10):110977. DOI: [10.1016/j.injury.2023.110977](https://doi.org/10.1016/j.injury.2023.110977)
14. Ren W, Gao L, Li S, et al. Virtual Planning and 3-D printing modeling for mandibular reconstruction with fibula free flap. *Med Oral Patol Oral Cir Bucal*. 2018;23(3):e359-e366. DOI: [10.4317/medoral.22295](https://doi.org/10.4317/medoral.22295)
15. Makarov IV, Karpova DO. Optimization of the tactics of surgical treatment of patients with hyperparathyroidism and chronic kidney disease. *Tavrisheskiy medico-biologicheskiy vestnik*. 2024;27(3):33-38. [Макаров И.В., Карпова Д.О. Оптимизация тактики хирургического лечения пациентов с гиперпаратиреозом и хронической болезнью почек. *Таврический медико-биологический вестник*. 2024;27(3):33-38]. URL: <https://ma.cfuv.ru/wp-content/uploads/2024/11/%D0%A2%D0%9C%D0%91%D0%92-%E2%84%963-2024.pdf>