Original study article | Оригинальное исследование
DOI: https://doi.org/10.35693/SIM691247

This work is licensed under CC BY 4.0
© Authors, 2025

Transmesenteric approach in the surgical treatment of left kidney cancer with venous tumor thrombus of Mayo levels 0–I

Musabek K. Mirzabekov, Mikhail I. Shkolnik, Oleg A. Bogomolov,

Granov Russian Research Center of Radiology and Surgical Technologies
(Saint Petersburg, Russian Federation)

Abstract

Aim – to evaluate the efficacy and safety an original transmesenteric approach for laparoscopic nephrectomy with thrombectomy in patients with left kidney cancer and venous tumor thrombus (levels 0–I according to the Mayo classification).

Material and methods. The study included 19 patients with histologically verified left kidney cancer who underwent laparoscopic nephrectomy with thrombectomy using a transmesenteric approach. Eleven patients had renal vein thrombus (Mayo level 0), and eight patients had thrombus extending into the inferior vena cava up to 2 cm from the renal vein orifice (Mayo level I). The following parameters were assessed: age, body mass index, operative time, intraoperative blood loss, hospital stay, and postoperative complications.

Results. All procedures were completed laparoscopically without conversion. The mean operative time was 125.8 ± 11.4 min, and the mean blood loss was 152.6 ± 62.9 ml. The mean hospital stay was 7.4 ± 0.6 days. No early or late complications were recorded. Operative time and blood loss were significantly lower compared to previously published series of laparoscopic and open procedures. Conclusion. The transmesenteric approach minimizes surgical trauma, reduces operative time and blood loss, and lowers the risk of complications while maintaining oncological radicality. The method can be recommended for widespread use in onco-urological practice.

Keywords: renal cell carcinoma; venous tumor thrombus; laparoscopic nephrectomy; thrombectomy; transmesenteric approach.

Conflict of interest: nothing to disclose.

Citation
Mirzabekov MK, Shkolnik MI, Bogomolov OA. **Transmesenteric approach in the surgical treatment of left kidney cancer with venous tumor thrombus of Mayo levels 0–I.** *Science and Innovations in Medicine.* 2025;10(4):321-326.
DOI: https://doi.org/10.35693/SIM691247

Information about authors
***Musabek K. Mirzabekov** – postgraduate student of the Department of Radiology, Surgery and Oncology.
ORCID: https://orcid.org/0009-0003-8365-7672
E-mail: Musabek.mirzabekoff@yandex.ru

Mikhail I. Shkolnik – MD, Dr. Sci. (Medicine), Associate professor, chief researcher, Professor of the Department of Radiology, Surgery and Oncology.
ORCID: https://orcid.org/0000-0003-0589-7999
E-mail: shkolnik_phd@mail.ru

Oleg A. Bogomolov – MD, Cand. Sci. (Medicine), senior researcher, Associate professor of the Department of Radiology, Surgery and Oncology.
ORCID: https://orcid.org/0000-0002-5860-9076
E-mail: urologbogomolov@gmail.com

Corresponding Author

Received: 03.09.2025
Accepted: 17.10.2025
Published: 27.10.2025

Трансмезентериальный доступ в хирургическом лечении рака левой почки с опухолевым венозным тромбозом 0–I уровня

М.К. Мирзабеков, М.И. Школьник, О.А. Богомолов

ФГБУ «Российский научный центр радиологии и хирургических технологий имени академика А.М. Гранова» Минздрава России (Санкт-Петербург, Российская Федерация)

Аннотация

Цель – оценить эффективность и безопасность оригинального трансмезентериального доступа при лапароскопической нефрэктомии с тромбэктомией у пациентов с раком левой почки и опухолевым венозным тромбозом 0–I уровня по классификации Mayo.

Материал и методы. В исследование включены 19 пациентов с верифицированным раком левой почки, которым выполнена лапароскопическая нефрэктомия с тромбэктомией трансмезентериальным доступом. У 11 больных выявлен тромб, ограниченный почечной веной (0 уровень по Mayo), у 8 – распространение тромба в нижнюю полую вену до 2 см от устья почечной вены (I уровень). Оценивались возраст, индекс массы тела, продолжительность операции, объем кровопотери, длительность госпитализации, наличие осложнений.

Результаты. Все вмешательства завершены лапароскопически, конверсий не потребовалось. Средняя продолжительность операции составила 125,8 ± 11,4 мин, средний объем кровопотери – 152,6 ± 62,9 мл. Средняя длительность госпитализации составила 7,4 ± 0,6 суток. Ранних и поздних осложнений в исследуемой группе не зарегистрировано. Показатели длительности операции и кровопотери были достоверно ниже, чем в опубликованных сериях лапароскопических и открытых операций.

Заключение. Трансмезентериальный доступ позволяет минимизировать травматичность вмешательства, сократить продолжительность операции, снизить кровопотерю и риск осложнений при сохранении онкологической радикальности. Методика может быть рекомендована для широкого применения в онкоурологической практике.

Ключевые слова: почечно-клеточный рак; опухолевый венозный тромбоз; лапароскопическая нефрэктомия; тромбэктомия; трансмезентериальный доступ.

Конфликт интересов: не заявлен.

Для цитирования:
Мирзабеков М.К., Школьник М.И., Богомолов О.А. **Трансмезентериальный доступ в хирургическом лечении рака левой почки с опухолевым венозным тромбозом 0–I уровня.** *Наука и инновации в медицине.* 2025;10(4):321-326.
DOI: https://doi.org/10.35693/SIM691247

Сведения об авторах
***Мирзабеков Мусабек Кямранович** – аспирант кафедры радиологии, хирургии и онкологии.
ORCID: https://orcid.org/0009-0003-8365-7672
E-mail: Musabek.mirzabekoff@yandex.ru
Школьник М.И. – д-р мед. наук, доцент, главный научный сотрудник, профессор кафедры радиологии, хирургии и онкологии.
ORCID: https://orcid.org/0000-0003-0589-7999
E-mail: shkolnik_phd@mail.ru
Богомолов О.А. – канд. мед. наук, старший научный сотрудник, доцент кафедры радиологии, хирургии и онкологии.
ORCID: https://orcid.org/0000-0002-5860-9076
E-mail: urologbogomolov@gmail.com
Автор для переписки

Список сокращений
ПКР – почечно-клеточный рак; НПВ – нижняя полая вена; ИМТ – индекс массы тела.

Получено: 03.09.2025
Одобрено: 17.10.2025
Опубликовано: 27.10.2025

INTRODUCTION

Renal cell cancer (RCC) remains a significant oncological problem in many countries [1]. According to the GLOBOCAN report, a total of 434,480 new cases of renal cancer were registered worldwide in 2022, and there is a tendency for the morbidity rate to grow (considering improved visualization techniques, demographic changes and such risk factors as obesity and arterial hypertension) [2]. In Russia, every year approx. 25,000 new cases of renal cancer are registered [3]. Epidemiologic data show that the age-standardized incidence rate in the Russian Federation is ca. 13-14 cases per 100,000 population for both men and women [4]. One of the characteristic features of RCC is the venous extension of the tumor: the venous tumor thrombus (VTT) is found in approx. 10% patients with RCC [5]. The growth of the thrombus level complicates the surgical approach, increases the risk of complications and impacts the prognosis [6].

To describe the incidence rate of the VTT, the Mayo classification is widely used (also known as the Mayo grading, or Mayo levels). Accordingly, the following levels are identified: 0 – tumor thrombus is limited to the renal vein; I – tumor thrombus extends to the inferior vena cava (IVC), apex < 2 cm from the venous entry; II – tumor thrombus extends into the IVC more than 2 cm above the entry but below the hepatic veins; III – tumor thrombus extends above the level of hepatic veins but below the diaphragm; IV – tumor thrombus extends above the diaphragm and may extend to the right atrium [7, 8].

The survival of RCC patients largely depends on the level of VTT and the presence of metastases, condition of lymph nodes and attendant characteristics of the tumor [9, 10]. In the Mayo Clinic experiment that analyzed 540 RCC patients and tumor thrombus over three decades, the five-year specific survival at thrombus level 0 was ca. 49.1%, while with the involvement of the IVC (levels I–II–III–IV), it was significantly lower (e.g., level I, ~31,7%, level II, ~26,3%) [11].

The study of Z. Chen *et al.* (2021), including 121 patients, demonstrated higher values of overall survival (OS) in thrombus levels 0 and I: 3-year OS was approx. 59%, 5-year OS, approx. 47%, in higher thrombus levels, 5-year OS lowered to ~32% [12]. In patients with thrombus levels 0–II, 5-year survival was approx. 46.7% [13]. Russian literary sources also report an increase in the diagnosing of the renal cancer, including that of early stages [14].

However, the data on the prevalence of the venous thrombosis, especially on levels 0–I, as well as detailed survival values for such patients in the Russian practice remain insufficient and fragmentary [15].

While the treatment standard of the renal cancer with venous tumor thrombus is the radical nephrectomy with thrombectomy, the technical aspects of the surgery remain a subject of discussion [16]. In order to adequately mobilize the left kidney, the traditional laparoscopic access requires dissection of the lienocolic and splenophrenic ligaments, as well as mobilization of the descending colon [14]. This increases the duration of the operation and involves risk of damaging the wall of the colon and of the spleen, which might result in serious intra- and postoperative complications.

Another problem is the necessity of mobilization of the ascending colon to ensure access to retroperitoneal space if the tumor thrombus has extended into the inferior vena cava [17]. Such manipulations involve the risk of injuring the liver and increase the probability of development of postoperative peritoneal adhesions and intestinal obstruction [18]. This necessitates development of new surgical methods that enable minimization of injury and improve results of surgery while preserving its radicality.

The designed method of laparoscopic mesenteric approach to the left kidney covered by the Russian Federation patent No.2803686 (dated 19.09.2023) enables minimization of the risks of the standard approach[1]. The access is achieved through the mesentery of the sigmoid colon, which excludes the necessity of mobilization of the mobilization of the descending colon and dissection of the lienocolic and splenophrenic ligaments. The method lowers the risk of injury of the colon and the spleen, reduces surgery time and increases its safety while providing an adequate approach to the inferior vena cava without a large-scale mobilization of the ascending colon. This reduces the probability of injuring the liver as well as the risk of postoperative adhesions. The surgery is performed with the patient in the supine position, ergonomically optimal both for the team of surgeons and anesthesiologists and for the patient. Lack of necessity of changing the body position during the operation further decreases the risks of implantation metastases and of the loss of sterility of the surgical area. Transmesenteric approach combines minimized injury, comfort of the patient's and the surgeon's positioning, as well as reproducibility, which allows regarding the method as an alternative to the standard laparoscopic approach.

[1] Мирзабеков М.К., Богомолов О.А., Школьник М.И. Патент РФ «Способ лапароскопической радикальной левосторонней нефрэктомии с тромбэктомией из нижней полой вены». Доступно по: https://patents.google.com/patent/RU2803686C1/ru

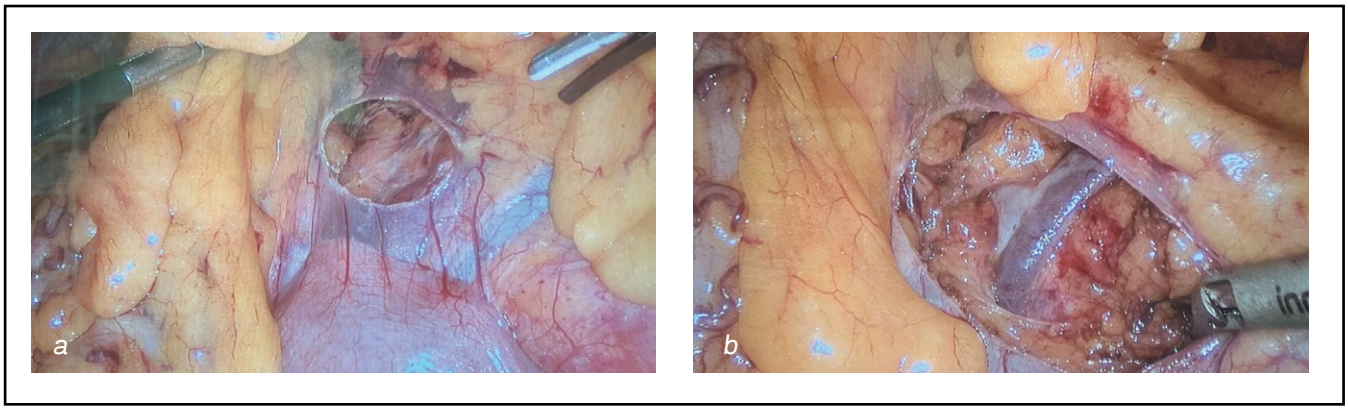

Figure 1. *Stages of transmesenteric approach formation: a – creation of a window in the mesentery of the descending colon; b – completed access to the left kidney, left renal vein with tumor thrombus in its lumen.*

Рисунок 1. *Этапы формирования трансмезентериального доступа: a – формирование «окна» в брыжейке нисходящей ободочной кишки; b – сформированный доступ к левой почке, левая почечная вена с опухолевым тромбом в ее просвете.*

AIM

To evaluate the efficacy and safety of using the original transmesenteric approach for laparoscopic nephrectomy with thrombectomy in patients with left kidney cancer and venous tumor thrombus (levels 0-I according to the Mayo classification).

MATERIAL AND METHODS

The study included 19 patients with histologically verified left kidney cancer with venous tumor thrombus who underwent laparoscopic nephrectomy with thrombectomy using a transmesenteric approach. Eleven patients had renal vein thrombus (Mayo level 0), and eight patients had thrombus extending into the inferior vena cava up to 2 cm from the renal vein orifice (Mayo level I).

Inclusion criteria: patients with left kidney cancer and venous tumor thrombus of levels 0-I as per Mayo classification, no remote metastases, ECOG 0-2 somatic status.

Exclusion criteria: identification of level II-IV thrombus, bilateral damage, severe comorbidities precluding the feasibility of laparoscopic intervention.

The surgical technique is illustrated with intraoperative images: formation of a 'window' in the mesentery of the descending colon and the final formed tramsmesenteric approach to the left kidney with visualization of the left renal vein (**Fig. 1**).

Study design: prospective single-center study.

Assessed parameters: age, body mass index (BMI), duration of the surgery, blood loss, duration of hospital stay, status of early (less than 30 days) and ate complications. The efficacy of the method was assessed with the feasibility of radical surgery without the need of conversion, level of blood loss and duration of the surgery. The safety was assessed with the aid of frequency of complications and specific features of the postoperative period.

Statistical processing of data was performed in the standard software suites (MedCalc; Microsoft Excel 2019). Quantitative indicators were described using mean values (M), standard deviation (SD), median (Me), minimum and maximum values, as well as 95% of confidence intervals (95% CI). The normality of quantitative data distribution was assessed using the Shapiro-Wilk test. For variables with approximately normal distribution, the single-sample Student's t-test was used. In cases of deviation from normality, the Wilcoxon signed-rank test was additionally applied. All comparisons were conducted using two-tailed tests at a statistical significance level of $p < 0.05$. For visual representation of the results, graphical visualization methods were used: histograms were constructed for the distribution of age, BMI, blood loss volume, duration of the surgery, and length of hospital stay (bed-days).

RESULTS

Out of the 19 patients with left kidney cancer, in 11 (57.9%) patients the thrombus was in the renal vein (level 0); in 8 (42.1%) patients, the thrombus extended to the inferior vena cava up to 2 from the renal vein orifice (level I).

The age of the patients varied from 54 to 76 years, the average age being 64.5 ± 5.6 years, median: 65 years (95% CI 61.8–67.2). **Fig. 2** shows patient distribution by age matching the symmetric normal distribution.

The mean BMI values was 26.0 ± 1.8 kg/m^2 (23.7 to 30.1 kg/m^2), median: 25.7 kg/m^2. The majority of patients had a normal or moderately elevated BMI, which is characteristic of the general distribution for individuals of this age group (**Fig. 3**).

The mean duration of hospital stay was 7.4 ± 0.6 days (7 to 9), median: 7 days (**Fig. 4**).

The majority of patients were discharged within the first week after the operation, which reflects the relatively low

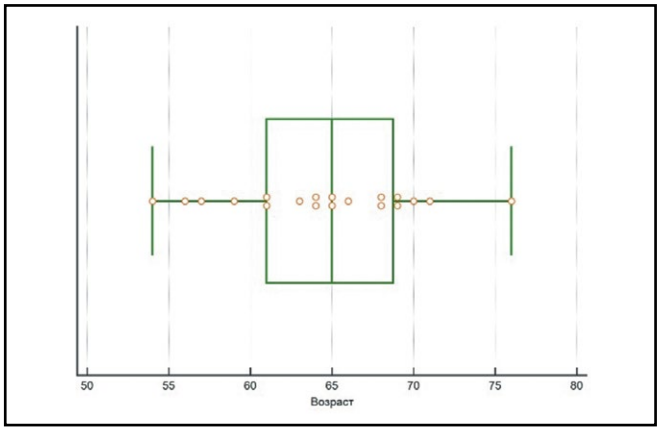

Figure 2. *Distribution of patient age in the study cohort (n = 19).*

Рисунок 2. *Распределение возраста пациентов, включенных в исследование (n = 19).*

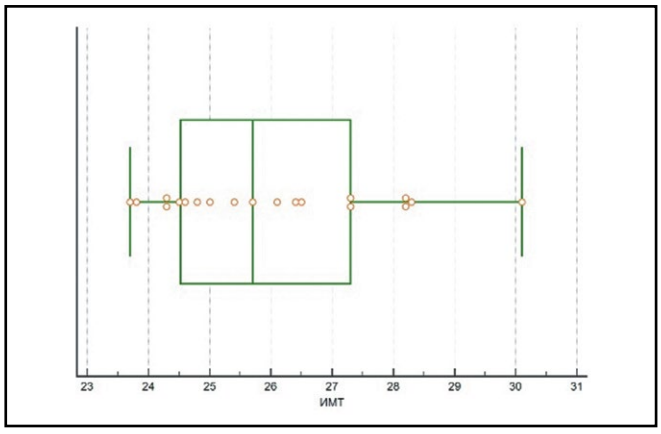

Figure 3. *Distribution of body mass index (BMI) in the study cohort (n = 19).*

Рисунок 3. *Распределение индекса массы тела (ИМТ) пациентов, включенных в исследование (n = 19).*

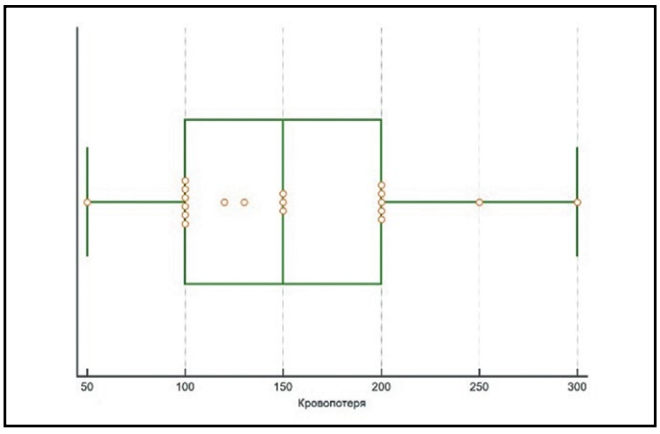

Figure 5. *Distribution of intraoperative blood loss in the study cohort (n = 19).*

Рисунок 5. *Распределение объема интраоперационной кровопотери у пациентов, включенных в исследование (n = 19).*

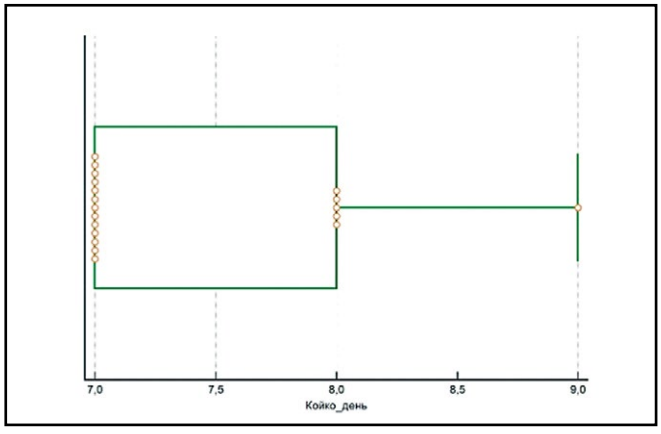

Figure 4. *Distribution of hospital stay (bed-days) in the study cohort (n = 19).*

Рисунок 4. *Распределение длительности госпитализации (койко-день) у пациентов, включенных в исследование (n = 19).*

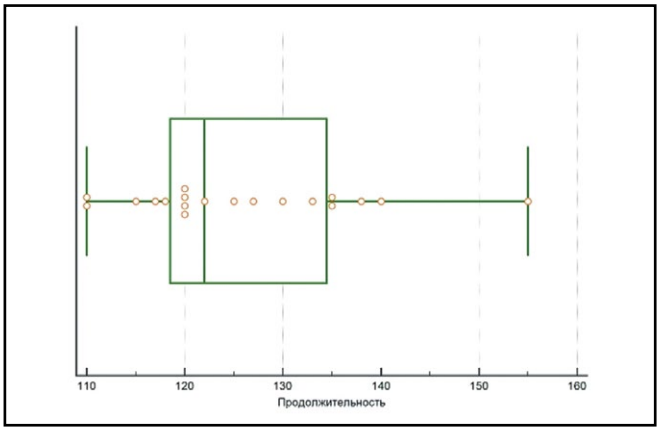

Figure 6. *Distribution of operative time in the study cohort (n = 19).*

Рисунок 6. *Распределение продолжительности операций у пациентов, включенных в исследование (n = 19).*

surgical injury of the operation and the favorable progression of the postoperative period.

The mean volume of intraoperative blood loss was 152.6 ± 62.9 mL (from 50 to 300 mL), median: 150 mL. In the majority of patients, the blood loss volume did not exceed 200 mL, confirming low surgical injury and sufficient visualization of the surgical area when using the transmesenteric approach (**Fig. 5**).

The mean duration of the laparoscopic nephrectomy with thrombectomy using a transmesenteric approach was 125.8 ± 11.4 minutes (110 to 155 min.), median: 122 minutes. The majority of surgeries lasted from 2 to 2.5 hours which is either comparable or less than series using the standard laparoscopic approach (**Fig. 6**).

DISCUSSION

The obtained results indicate that the use of the transmesenteric approach in laparoscopic nephrectomy with thrombectomy in patients with Mayo level 0-I tumor thrombus enables high efficacy and safety. When comparing it with the literature data, our findings were more favorable: in the studies of P. Dell'Oglio et al. (2024), the average duration of such surgeries was 180–240 min., and the volume of blood loss often exceeded 500 mL [19]; in the retrospective series of Z. Chen *et al.* (2021), the average blood loss reached 400 mL, with complications observed in 15-20% of patients [12]. Thus, the transmesenteric approach allowed for a substantial minimization of the surgical trauma and ensure a high level of safety. The average duration of the surgery was 125.8 min., average blood loss was 152.6 mL, average duration of the hospital stay was 7.4 days; no complications or conversions to an open surgery were reported. These indicators are either comparable or superior to the data found in literature for standard laparoscopic surgeries [20].

The major advantage of the transmesenteric approach described in the Russian Federation patent No. 2803686 (2023) is lack of necessity to mobilize the descending colon and dissection of the splenic ligaments when approaching the left kidney. The additional factor favorable for the outcomes is the possibility of accessing the IVC without mobilization of the ascending colon, lowering the probability of liver injury and the risk of adhesion complications.

A significant advantage is the performance of the surgery with the patient in the supine position, which ensures ergonomics for the surgical team and optimal conditions for anesthetic management. The absence of the need for patient repositioning reduces surgery time, decreases the likelihood of compromised sterility, and lowers the risks of tumor migration

and implantation metastasis. Combined, these factors demonstrate the suggested approach as a safer, physiological alternative to the standard laparoscopic approach in cases of renal cancer with low-level thrombosis.

The limitations of this study are the low size of the sample and the single-center character of observation, which precludes extrapolation of the obtained data to a wider cohort. Besides, the study assessed only the early results without the analysis of the remote oncological outcomes. Nevertheless, the obtained data confirm the prospects and the reproducibility of the method forming the foundation for its further use in clinical practice.

The presented results show that the transmesenteric approach offers a number of advantages, making it potentially applicable not only in laparoscopic surgery but also in the context of robot-assisted interventions. The ergonomics of access with the patient in the supine position fully meets the capabilities of robotic complexes, and the excluded need for mobilization of the colon simplifies the dissection stages and reduces operative time, which is especially important in the conditions of operating space and necessity of least invasive manipulations with the vessels.

A promising direction is the expansion of indications for the use of the transmesenteric approach in Mayo level II venous tumor thrombus. With this level of IVC involvement, a much wider surgical access is required, which is associated with an increased risk of complications. At the same time, the anatomic specifics of transmesenteric approach allow for a direct adequate view of vascular structures, which could theoretically improve the safety of operations for this category of patients. The final verification of these advantages requires studies on larger cohorts of patients including both laparoscopic and robot-assisted operations, as well as analysis of oncological outcomes in the long term. The proposed method not only expands the capabilities of laparoscopic surgery in renal cancer with low-level venous tumor thrombus but also opens prospects of integration with contemporary minimally invasive technologies.

CONCLUSION

Implementation of transmesenteric approach into clinical practice allows for a significant increase in safety and reproducibility of laparoscopic nephrectomy with thrombectomy in patients with level 0-I venous tumor thrombus. The use of this technique reduces operative time, decreases the extent of organ mobilization and the risk of their injury, and minimizes the likelihood of postoperative complications. This method can be recommended for widespread adoption in oncourology centers and is considered promising for adaptation to robot-assisted surgery platforms.

ADDITIONAL INFORMATION	ДОПОЛНИТЕЛЬНАЯ ИНФОРМАЦИЯ
Ethics approval. The study was approved by the LEC of Granov Russian Research Center of Radiology and Surgical Technologies (extract from protocol № 03-11/2021 dated 18.11.2021).	***Этическая экспертиза.*** Проведение исследования одобрено ЛЭК ФГБУ «РНЦРХТ им. ак. А.М. Гранова» (выписка из протокола № 03-11/2021 от 18.11.2021).
Consent for publication: All patients signed a written informed consent form.	***Согласие на публикацию.*** Все пациенты подписывали добровольное информированное согласие.
Study funding. The study was the authors' initiative without external funding.	***Источник финансирования.*** Работа выполнена по инициативе авторов без привлечения финансирования.
Conflict of interest. The authors declare that there are no obvious or potential conflicts of interest associated with the content of this article.	***Конфликт интересов.*** Авторы декларируют отсутствие явных и потенциальных конфликтов интересов, связанных с содержанием настоящей статьи.
Contribution of individual authors. Mirzabekov M.K.: concept development, statistical analysis, text preparation. Shkolnik M.I., Bogomolov O.A.: text editing and approval. All authors gave their final approval of the manuscript for submission, and agreed to be accountable for all aspects of the work, implying proper study and resolution of issues related to the accuracy or integrity of any part of the work.	***Участие авторов.*** Мирзабеков М.К. – разработка концепции, проведение статистического анализа, подготовка текста. Школьник М.И., Богомолов О.А. – редактирование и утверждение текста. Все авторы одобрили финальную версию статьи перед публикацией, выразили согласие нести ответственность за все аспекты работы, подразумевающую надлежащее изучение и решение вопросов, связанных с точностью или добросовестностью любой части работы.
Statement of originality. No previously published material (text, images, or data) was used in this work.	***Оригинальность.*** При создании настоящей работы авторы не использовали ранее опубликованные сведения (текст, иллюстрации, данные).
Data availability statement. The editorial policy regarding data sharing does not apply to this work.	***Доступ к данным.*** Редакционная политика в отношении совместного использования данных к настоящей работе не применима.
Generative AI. No generative artificial intelligence technologies were used to prepare this article.	***Генеративный искусственный интеллект.*** При создании настоящей статьи технологии генеративного искусственного интеллекта не использовали.
Provenance and peer review. This paper was submitted unsolicited and reviewed following the standard procedure. The peer review process involved 2 external reviewers.	***Рассмотрение и рецензирование.*** Настоящая работа подана в журнал в инициативном порядке и рассмотрена по обычной процедуре. В рецензировании участвовали 2 внешних рецензента.

REFERENCES / ЛИТЕРАТУРА

1. Veronese N, Custodero C, Cella A, et al. Prevalence of multidimensional frailty and pre-frailty in older people in different settings: A systematic review and meta-analysis. *Ageing Res Rev*. 2023;92:101874. DOI: 10.1016/j.arr.2021.101498

2. Bray F, Laversanne M, Sung H, et al. Global cancer statistics 2022: GLOBOCAN estimates of incidence and mortality worldwide for 36 cancers in 185 countries. *CA Cancer J Clin*. 2024;74(3):229-263. DOI: 10.3322/caac.21834

3. Kaprin AD, Starinsky VV, Petrova GV, et al. *Malignant neoplasms in Russia in 2021 (morbidity and mortality)*. M., 2022. (In Russ.). [Каприн А.Д., Старинский В.В., Петрова Г.В., и др. *Злокачественные новообразования в России в 2021 году (заболеваемость и смертность)*. М., 2022]. URL: https://glavonco.ru/cancer_register/MT_2021.pdf

4. Capitanio U, Bensalah K, Bex A, et al. Epidemiology of Renal Cell Carcinoma. *European Urology*. 2019;75(1):74-84. DOI: 10.1016/j.eururo.2018.08.036

5. World Cancer Research Fund. Kidney cancer statistics. *World Cancer Research Fund International*. 2022. URL: https://www.wcrf.org/preventing-cancer/cancer-statistics/kidney-cancer-statistics/

6. Zhuo Liu, Xun Zhao, Liyuan Ge, et al. Completely laparoscopic versus open radical nephrectomy and infrahepatic tumor thrombectomy: Comparison of surgical complexity and prognosis. *Asian Journal of Surgery*. 2021;44(4):641-648. DOI: 10.1016/j.asjsur.2020.12.003

7. Altinay M, Oba S. Predictors of mortality in elderly patients in emergency abdominal surgery: a retrospective single-center study. *J Surg Med*. 2023;7(10):646-650. DOI: 10.28982/josam.7972

8. Marahanumaiah S, Suresh N, Rajkumar B, et al. Impact of obesity on surgical outcomes in patients undergoing emergency laparotomy: a prospective observational study. *Cureus*. 2025;17(6):e85887. DOI: 10.7759/cureus.85887

9. Lardas M, Stewart F, Scrimgeour D, et al. Systematic Review of Surgical Management of Nonmetastatic Renal Cell Carcinoma with Vena Caval Thrombus. *European Association of Urology*. 2016;70(2):265-80. DOI: 10.1016/j.eururo.2015.11.034

10. Volkova MI, Vashakmadze NL, Klimov AV, et al. Prognosis of patients operated on for renal cell carcinoma and tumor venous thrombosis: experience of the Urology Clinics, N.N. Blokhin National Medical Research Center of Oncology. *Cancer Urology*. 2021;17(3):19-28. [Волкова М.И., Вашакмадзе Н.Л., Климов А.В., и др. Прогноз у пациентов, оперированных по поводу почечно-клеточного рака и опухолевого венозного тромбоза: опыт работы урологических клиник НМИЦ онкологии им. Н.Н. Блохина. *Онкоурология*. 2021;17(3):19-28]. DOI: 10.17650/1726-9776-2021-17-3-19-28

11. Mayo Clinic. Outcomes for patients with renal tumors and venous tumor thrombus. *Mayo Clinic Professional*. 2023. URL: https://www.mayoclinic.org/medical-professionals/urology/news/outcomes-for-patients-with-renal-tumors-and-venous-tumor-thrombus/mac-20570379

12. Chen Z, Zhang H, Liu H, et al. Outcomes of renal cell carcinoma with associated venous tumor thrombus: experience from a large cohort and short time span in a single center. *BMC Cancer*. 2021;21:766. DOI: 10.1186/s12885-021-08508-x

13. Leibovich BC, Cheville JC, Lohse CM, et al. A scoring algorithm to predict survival for patients with metastatic clear cell renal cell carcinoma: A stratification tool for prospective clinical trials. *Journal of Urology*. 2005;174(5):1759-1763. DOI: 10.1097/01.ju.0000177487.64651.3a

14. Mirzabekov MK, Bogomolov OA, Shkolnik MI, et al. Comparative analysis of survival rates in patients with renal cell carcinoma and level I–II tumor thrombus of the renal vein and inferior vena cava undergoing open versus laparoscopic surgical treatment. *Perm Medical Journal*. 2025;42(4):105-114. [Мирзабеков М.К., Школьник М.И., Богомолов О.А., и др. Сравнительный анализ показателей выживаемости пациентов с почечно-клеточный раком и опухолевым тромбозом почечной и нижней полой вены I–II уровня, подвергшихся хирургическому лечению открытым и лапароскопическим доступом. *Пермский медицинский журнал*. 2025;42(4):105-114]. DOI: 10.17816/pmj424105-114

15. Nosov AK, Lushina PA. Kidney cancer incidence and mortality in Russia and Saint-Petersburg. *Siberian journal of oncology*. 2017;16(5):95-103. [Носов А.К., Лушина П.А. Анализ заболеваемости и смертности от рака почки в России и Санкт-Петербурге. *Сибирский онкологический журнал*. 2017;16(5):95-103]. DOI: 10.21294/1814-4861-2017-16-5-95-103

16. Davydov MI, Matveev VB, Volkova MI, et al. Surgical treatment of renal cell carcinoma with advanced tumor invasion of the inferior vena cava. *Cancer Urology*. 2017;13(1):27-36. [Давыдов М.И., Матвеев В.Б., Волкова М.И., и др. Хирургическое лечение почечно-клеточного рака с инвазией в нижнюю половую вену. *Онкоурология*. 2017;13(1):27-36. DOI: 10.17650/1726-9776-2017-13-1-27-36

17. Atduev VA, Amoev ZV, Danilov AA, et al. Surgical treatment of kidney cancer with extended inferior vena cava thrombi: complications and long-term results. *Cancer Urology*. 2017;13(1):37-44. [Атдуев В.А., Амоев З.В., Данилов А.А., и др. Хирургическое лечение рака почки с протяженными тромбами нижней полой вены: осложнения и отдаленные результаты. *Онкоурология*. 2017;13(1):37-44]. DOI: 10.17650/1726-9776-2017-13-1-37-44

18. Campi R, Tellini R, Sessa F, et al. Techniques and outcomes of minimally-invasive surgery for nonmetastatic renal cell carcinoma with inferior vena cava thrombosis: a systematic review of the literature. *Minerva Urol Nefrol*. 2019;71(4):339-358. DOI: 10.23736/S0393-2249.19.03396-4

19. Dell'Oglio P, Tappero S, Mandelli G, et al. Surgical and oncological outcomes of level III–IV versus level I–II inferior vena cava thrombectomy: A decennial experience of a high-volume European Referral Center. *Annals of Surgical Oncology*. 2024;31(12):8383-8393. DOI: 10.1245/s10434-024-15878-6

20. Rose KM, Navaratnam AK, Faraj KS, et al. Comparison of Open and Robot-Assisted Radical Nephrectomy with Level I and II Inferior Vena Cava Tumor Thrombus: The Mayo Clinic Experience. *Urology*. 2020;136:152-157. DOI: 10.1016/j.urology.2019.11.002